

岩手医科大学  
審査学位論文  
(博士)

Received:  
10 November 2015

Revised:  
1 April 2016

Accepted:  
4 May 2016

<http://dx.doi.org/10.1259/bjr.20150938>

Cite this article as:

Kawashima K, Kato K, Tomabechi M, Matsuo M, Otsuka K, Ishida K, et al. Clinical evaluation of  $^{18}\text{F}$ -fludeoxyglucose positron emission tomography/CT using point spread function reconstruction for nodal staging of colorectal cancer. *Br J Radiol* 2016; **89**: 20150938.

## SHORT COMMUNICATION

# Clinical evaluation of $^{18}\text{F}$ -fludeoxyglucose positron emission tomography/CT using point spread function reconstruction for nodal staging of colorectal cancer

<sup>1</sup>KAZUYA KAWASHIMA, MD, <sup>1</sup>KENICHI KATO, MD, <sup>1</sup>MAKIKO TOMABECHI, MD, <sup>1</sup>MIKARU MATSUO, MD, <sup>2</sup>KOKI OTSUKA, MD, <sup>3</sup>KAZUYUKI ISHIDA, MD, <sup>4</sup>RYUJI NAKAMURA, MD and <sup>1</sup>SHIGERU EHARA, MD

<sup>1</sup>Department of Radiology, Iwate Medical University, Morioka, Japan

<sup>2</sup>Department of Surgery, Iwate Medical University, Morioka, Japan

<sup>3</sup>Department of Pathology, Iwate Medical University, Morioka, Japan

<sup>4</sup>PET Linac Center, Iwate Medical University, Morioka, Japan

Address correspondence to: Dr Kazuya Kawashima

E-mail: [m24\\_kawakazuimu@yahoo.co.jp](mailto:m24_kawakazuimu@yahoo.co.jp)

**Objective:** For patients with colorectal cancer, lymph node metastasis is a very important factor for prognostic and treatment determinations. Fluorine-18 fludeoxyglucose positron emission tomography/CT ( $^{18}\text{F}$ -FDG-PET/CT) is among the useful tools for detecting lymph node metastasis. Recently, a new  $^{18}\text{F}$ -FDG-PET/CT reconstruction technique for improving spatial resolution and signal-to-noise ratios, point spread function (PSF), has become available. We assessed the effect of PSF reconstruction on standardized uptake values and its diagnostic accuracy for lymph node staging in patients with colorectal cancer.

**Methods:** We retrospectively analysed records from patients with colorectal cancer who underwent  $^{18}\text{F}$ -FDG-PET/CT for pre-operative staging. All positron emission tomography CT (PET/CT) examinations were reconstructed using ordered subset expectation maximization (OSEM) and OSEM + PSF. We compared sensitivities, specificities, positive-predictive values (PPVs), negative-predictive values (NPVs) and accuracies of conventional PET/CT (reconstructed with OSEM)

and PSF-PET/CT (reconstructed with OSEM + PSF) for identifying lymph node metastases. We also analysed the diagnostic confidence level on a 5-point scale.

**Results:** With conventional PET/CT, the sensitivity, specificity, PPV, NPV and accuracy were 53.1%, 99.1%, 94.4%, 88.3% and 89.1%, respectively. With PSF PET/CT, the corresponding values were 65.6%, 99.1%, 95.4%, 91.2% and 91.8%, respectively. Conventional PET/CT and PSF PET/CT did not differ significantly in terms of *N*-stage definition ( $p = 0.125$ ). However, the diagnostic confidence level of PSF PET/CT was significantly higher than that of conventional PET/CT ( $p < 0.01$ ).

**Conclusion:** PSF reconstruction might slightly increase sensitivity without impairing specificity. Moreover, this technique is expected to facilitate more confident radiological decisions when compared with conventional PET/CT.

**Advance in knowledge:** This study demonstrates the clinical effectiveness of PSF PET/CT for lymph node staging in colorectal cancer.

## INTRODUCTION

For patients with colorectal cancer, lymph node metastasis is a very important prognostic factor.<sup>1</sup> Contrast-enhanced CT is most commonly used to detect lymph node metastasis of colorectal cancer. However, CT provides only morphological data, and it may be difficult to distinguish lymph nodes from surrounding normal structures in lean patients. Accordingly, CT does not have a high diagnostic sensitivity for lymph node metastasis.<sup>2</sup> By contrast, fluorine-18 fludeoxyglucose positron emission tomography/CT ( $^{18}\text{F}$ -FDG-PET/CT) can provide functional information, in addition to anatomical information.  $^{18}\text{F}$ -FDG-PET/CT reflects the metabolic abnormalities that precede morphological abnormalities and

is therefore useful for detecting lymph node metastasis.<sup>3</sup> The main advantage of positron emission tomography (PET) over other imaging modalities is that quantitative images can be obtained. In particular, the standardized uptake value (SUV), extracted from  $^{18}\text{F}$ -FDG/PET-CT data, has been widely used as a non-invasive quantitative imaging biomarker in the field of oncology. In addition to the metabolic status of the tissue, SUV is affected by various factors such as device-specific sensitivity, imaging conditions and image reconstruction conditions. Recently, a new  $^{18}\text{F}$ -FDG-PET/CT reconstruction technique, the point spread function (PSF), has become commercially available via equipment such as Sharp IR (GE Healthcare)

and HD; TrueX (Siemens Medical Solutions). The PSF describes the response of an imaging system to a point source or point object. Using a reconstruction algorithm with PSF modelling, the response lines can be located in their actual positions. Therefore, PSF improves the spatial resolution and signal-to-noise ratio of PET images.<sup>4,5</sup> However, this new PET/CT reconstruction method has only been used in a few clinical investigations of cancers such as breast or lung cancer.<sup>6–8</sup> The purpose of the present study was to evaluate the usefulness of <sup>18</sup>F-FDG-PET/CT with PSF reconstruction for lymph node staging in patients with colorectal cancer.

## METHODS AND MATERIALS

### Patient selection

We retrospectively reviewed patients with colorectal cancer who underwent <sup>18</sup>F-FDG-PET/CT at our institute from March 2013 to July 2015. The inclusion criterion was a pre-operative examination for colorectal cancer staging. The exclusion criteria were (1) a serum glucose concentration  $>150$  mg dl<sup>-1</sup> before fluorine-18 fludeoxyglucose (<sup>18</sup>F-FDG) administration, (2) no lymph node dissection during surgery and (3) pre-operative radiation therapy or chemotherapy after PET evaluation. The institutional review board of our institution approved this study.

### Positron emission tomography/CT protocol

All PET/CT scans were performed on a Discovery™ PET/CT 600 Motion apparatus (GE Healthcare, Milwaukee, WI) with a 16-slice multidetector-row CT component. All patients fasted for at least 4 h before the PET/CT examination. Following an injection of <sup>18</sup>F-FDG (mean injected activity  $3.93 \pm 0.67$  MBq kg<sup>-1</sup>), all patients were instructed to rest for 60 min before scanning. Patients were required to urinate before scanning to reduce tracer accumulation in the bladder. CT acquisition was performed first using the following parameters: tube voltage, 120 kV; tube current, CT auto exposure control; pitch factor, 1.375; table rotation,  $27.5$  mm s<sup>-1</sup>; and slice thickness, 3.75 mm. PET emission acquisition was subsequently performed in three-dimensional mode from the head to the mid-thigh. In order to establish a suitable acquisition time, the acquisition time was personalized based on the measured count rate between the subpubis and thigh.<sup>9</sup> The duration was set individually from 1 min 30 s to 4 min 50 s for each bed position. The three-dimensional ordered subset expectation maximization reconstruction method was used (VUE point HD; GE Healthcare). The following reconstruction parameters were used for conventional PET: 16 subsets; 2 iterations; Gaussian filter at full width at half maximum of 6; matrix size,  $128 \times 128$ ; pixel size, 4.69; and Z-axis filter, standard. The following reconstruction parameters were used for PSF PET: 8 subsets; 5 iterations; Gaussian filter at full width at half maximum of 0; matrix size,  $252 \times 256$ ; pixel size, 2.34; Z-axis filter, standard + PSF algorithm (Sharp IR). All PET data were routinely reconstructed using both conventional PET and PSF PET and were used for the diagnostic work-up during this study period. For quality assurance and quality control, the PET procedure was performed according to the Japanese Society of Nuclear Medicine guidelines.

### Positron emission tomography/CT interpretation of lymph nodes

Patient information was anonymized, randomized and reviewed on a GE Advantage Workstation v. 4.5 (GE Healthcare). Two radiologists (K Kato and M Tomabechi) with more than 5 years' experience reading both conventional PET/CT and PSF PET/CT images independently interpreted the lymph node staging. Lymph nodes were evaluated based on increased metabolism relative to the surrounding lymph nodes but independent of size. Lymph nodes were classified as regional and distant lymph nodes in accordance with the criteria of the Japanese Society for Cancer of the Colon and Rectum, eighth edition.<sup>10</sup> Regional lymph nodes were defined as those located along the peripheral vessels and proximal to the primary tumour. Distant lymph nodes were defined as nodes along the superior mesenteric artery, inferior mesenteric artery, ileocolic artery, right colic artery, middle colic artery, left colic artery, sigmoid arteries or superior rectal artery and in the para-aortic region. All lymph nodes were numbered in groups based on their anatomical locations in accordance with the criteria of "Japanese Society for Cancer of the Colon and Rectum", and nodal staging was performed on a per-lymph node group basis. When two or more lymph nodes were diagnosed as malignant in each group, the lymph node with the highest maximum SUV (SUV<sub>max</sub>) was selected as representative of the group and evaluated in this study.

Table 1. Demographics and clinicopathological characteristics of the patients

Number of patients	38
Sex (M, F)	22, 16
Median age, years (range)	62.5 (27–85)
Mean interval in days from PET/CT to operation (range)	17.0 (3–4)
Primary tumour location	
Caecum	1
Ascending colon	1
Transverse colon	2
Descending colon	0
Sigmoid colon	5
Rectum	29
Histological diagnosis	
Well-differentiated adenocarcinoma	2
Moderately differentiated adenocarcinoma	34
Poorly differentiated adenocarcinoma	2
Pathological stage (UICC)	
I	4
II	7
III	16
IV	11

F, female; M, male; PET, positron emission tomography; UICC, Union for International Cancer Control.

Observers reported the locations of abnormal lymph nodes, measured sizes and SUV<sub>max</sub> and determined the level of diagnostic confidence using the following scale: 0, definitely not metastasis; 1, probably not metastasis; 2, possibly metastasis; 3, probably metastasis; and 4, definitely metastasis. Grades of 3–4 and 0–2 were considered malignant and benign, respectively. In cases of disagreement, a consensus panel comprising both the original observers and a third experienced radiologist made the final decision. These diagnostic findings were compared with surgical findings and histopathological analyses of harvested lymph nodes, which comprised the gold standard. Observers additionally calculated the SUV<sub>max</sub> of the primary tumour.

### Statistical analyses

All statistical analyses were performed using Stat Mate V (ATMS Co., Ltd, Tokyo, Japan) and Prism® (GraphPad Software, La Jolla, CA). Regarding comparisons of conventional PET/CT and PSF PET/CT data, the *t*-test was used to evaluate SUV<sub>max</sub> and the McNemar test was used for sensitivity, specificity, positive-predictive value, negative-predictive value and accuracy. The Wilcoxon signed-rank test was also used to compare the level of diagnostic confidence in the radiologists' interpretations. *p*-values <0.05 were considered statistically significant.

## RESULTS

### Clinical data

54 patients met the study inclusion criteria; of these, 14 patients who underwent radiation therapy or chemotherapy before surgery and 2 who had serum glucose concentrations >150 mg dl<sup>-1</sup> prior to <sup>18</sup>F-FDG administrations were excluded. Finally, 38 patients were enrolled in this study. The clinical data of these 38 patients are summarized in Table 1. 9 patients were diagnosed with colon cancer (23%) and 29 (76%) were diagnosed with rectal cancer. Regarding stage distribution, 4, 7, 16 and 11 patients were classified as Stage I, II, III and IV, respectively. Regarding histopathological results, 147 groups of lymph nodes were harvested. The prevalence of metastasis among groups with lymph node involvement was 21.7% (32/147). 1 of 38 patients could not undergo para-aortic lymph node resection, despite positive PET findings, because of an emergent condition and very advanced stage. This lymph node group was excluded from our analysis.

### Amplification of SUV<sub>max</sub> on PSF PET/CT

The relationship between the conventional PET/CT SUV<sub>max</sub> and PSF PET/CT SUV<sub>max</sub> is shown in Table 2. The mean primary tumour SUV<sub>max</sub> extracted from conventional PET/CT and PSF

PET/CT were 13.6 and 20.0, respectively; the latter was significantly higher than the former (*p* < 0.001). It was impossible to measure size and SUV<sub>max</sub> in six groups of lymph nodes because they involved primary tumours and could not be distinguished from the primary tumours on PET/CT image. Excluding these six lymph nodes, the mean SUV<sub>max</sub> of metastatic lymph nodes extracted from conventional PET/CT and PSF PET/CT were 3.1 and 4.1, respectively. For metastatic lymph nodes with short axis diameters <10 mm, the mean SUV<sub>max</sub> extracted using conventional PET/CT and PSF PET/CT were 2.4 and 3.0, respectively. For metastatic lymph nodes with short axis diameters >10 mm, the corresponding mean values were 4.4 and 6.3, respectively. Notably, the mean SUV<sub>max</sub> of lymph node metastasis was significantly higher when extracted using PSF PET/CT than when extracted using conventional PET/CT (*p* < 0.001). In addition, the regression analysis indicated a statistically weak correlation between the lymph node size and the PSF to conventional SUV<sub>max</sub> ratio (Figure 1). In other words, the PSF to conventional SUV<sub>max</sub> ratio tended to increase along with the lymph node size.

### Diagnostic performance of conventional PET/CT vs PSF PET/CT for nodal staging

For lymph node metastasis confirmation, conventional PET/CT yielded a sensitivity, specificity, positive-predictive value, negative-predictive value and accuracy of 53.1%, 99.1%, 94.4%, 88.3% and 89.1%, respectively. PSF PET/CT yielded corresponding values were 65.6%, 99.1%, 95.4%, 91.2% and 91.8%, respectively (Table 3). Both imaging techniques yielded false-positive findings for the same single lesion among the 147 analysed lesions. However, four false-negative lesions detected using conventional PET/CT were correctly diagnosed as true-positive lesions with PSF PET/CT (Figure 2).

We also evaluated diagnostic performance according to the lymph node location. A comparison of conventional PET/CT and PSF PET/CT with regard to the detection of regional and distant lymph node metastasis is shown in Table 4. Notably, PSF PET/CT tended to have higher sensitivity relative to conventional PET/CT. However, this difference was not statistically significant. In addition, PSF PET/CT images afforded the radiologists a significantly higher level of confidence than did conventional PET/CT images, according to the results of a Wilcoxon signed-rank analysis (*p* < 0.01).

## DISCUSSION

For colorectal cancers, lymph node metastasis is an important factor with regard to prognostic and treatment determinations.

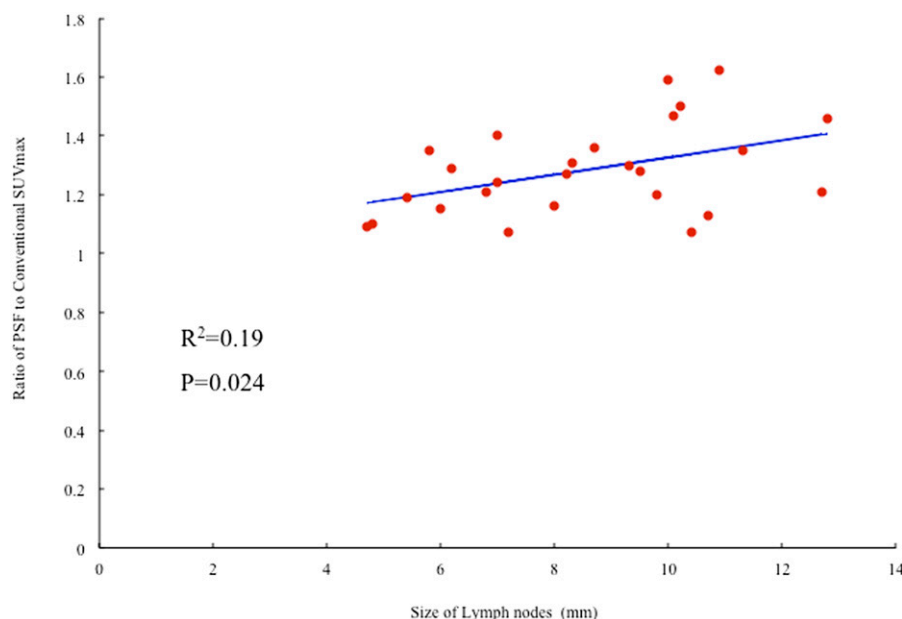
Table 2. Relationship of maximum standard uptake value (SUV<sub>max</sub>) between conventional positron emission tomography (PET)/CT and point spread function (PSF) PET/CT

	Conventional PET/CT	PSF PET/CT	<i>p</i> -values <sup>a</sup>
Primary tumour ( <i>n</i> = 38)	13.6	20.0	<0.001
Total nodes <sup>b</sup> ( <i>n</i> = 26)	3.1	4.1	<0.001
Nodes <1 cm ( <i>n</i> = 17)	2.4	3.0	<0.001
Nodes ≥1 cm ( <i>n</i> = 9)	4.4	6.3	<0.01

<sup>a</sup>*t*-test.

<sup>b</sup>Size and SUV<sub>max</sub> of six lymph nodes were unmeasurable.

Figure 1. Relationship between lymph node size and the point spread function (PSF) to conventional fluorine-18 fludeoxyglucose positron emission tomography/CT maximum standard uptake value (SUV<sub>max</sub>) ratio. The regression analysis showed a weak statistical correlation between the lymph node size and the PSF to conventional SUV<sub>max</sub> ratio.



Notably, the diagnostic utility of PET/CT for lymph node staging has been described,<sup>11,12</sup> and recent technological advances, such as the addition of PSF to algorithm reconstructions, have improved the spatial resolution and signal-to-noise ratio. However, clinical studies involving <sup>18</sup>F-FDG-PET/CT with PSF reconstruction are lacking. Although a few authors have reported the effectiveness of PSF PET/CT for pulmonary or breast cancers,<sup>6–8</sup> to the best of our knowledge, this is the first study to investigate the reliability of PSF-extracted SUV with regard to colorectal cancers.

As in previous reports of pulmonary or breast cancers, our study demonstrated that the implementation of PSF significantly increased the SUV<sub>max</sub> in both primary colorectal tumours and lymph node metastases. In our study, the acquisition times were personalized based on the measured count rate between the subpubis and thigh through the detectors of the PET system.<sup>9</sup> Different bed times were targeted for standardizing the acquisition true counts and reduced the influence on SUV<sub>max</sub> to the lowest level possible, independent of the administrated dose of <sup>18</sup>F-FDG and body mass index. Although the diagnostic

performances of conventional PET/CT and PSF PET/CT did not differ significantly in terms of N-stage definition, PSF PET/CT had a significantly higher diagnostic confidence level than conventional PET/CT.

In this study, we categorized lymph nodes as regional or distant, depending on their anatomical location. We did not find a statistically significant difference between conventional PET/CT and PSF PET/CT in the detection of regional and distant lymph node metastases. However, PSF PET/CT exhibited better sensitivity for distant nodal staging than regional nodal staging. Tsunoda *et al*<sup>13</sup> also noted that the sensitivity of <sup>18</sup>F-FDG-PET/CT was lower for regional lymph nodes than for distant lymph nodes. These authors assumed that lymph nodes near a primary tumour could not be distinguished from the tumour or from physiological uptake on <sup>18</sup>F-FDG-PET/CT, thus reducing the sensitivity at proximal sites.

This study has had some limitations. All enrolled patients were pre-operative cases and were compared with gold-standard histopathological results. Additionally, patients with advanced-

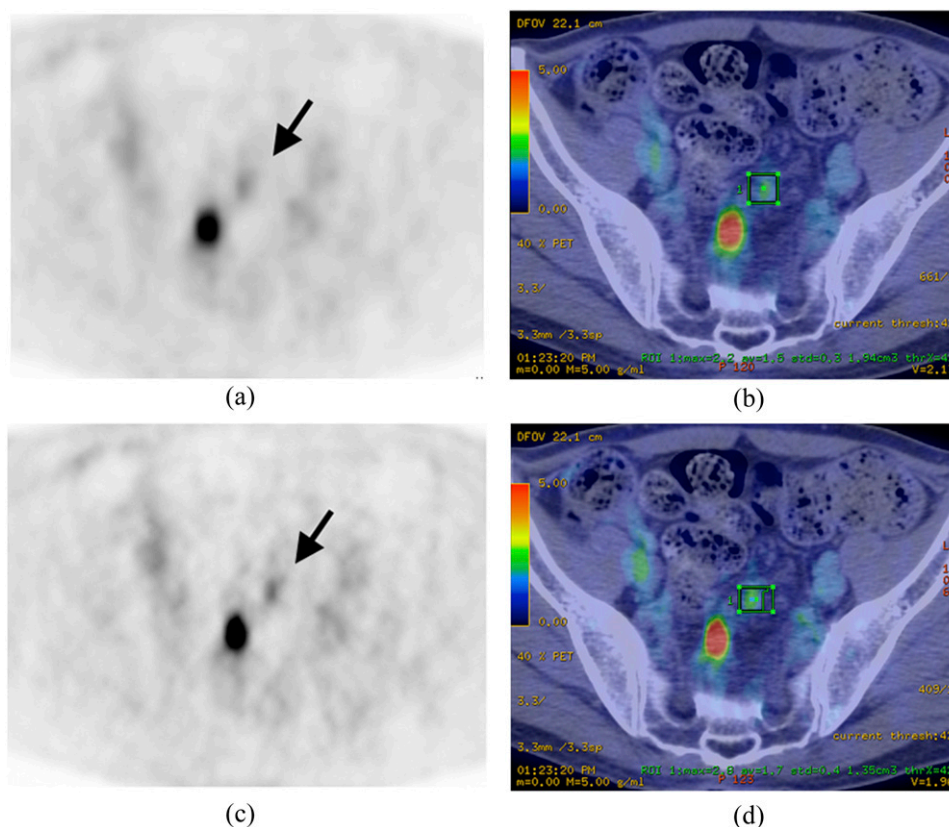
Table 3. Diagnostic performance of conventional positron emission tomography (PET)/CT vs point spread function (PSF) PET/CT

	Conventional PET/CT	PSF PET/CT	<i>p</i> -value <sup>a</sup>
Sensitivity (%)	53.1	65.6	NS ( <i>p</i> = 0.125)
Specificity (%)	99.1	99.1	
PPV (%)	94.4	95.4	
NPV (%)	88.3	91.2	
Accuracy (%)	89.1	91.8	

NPV, negative-predictive value; NS, not significant; PPV, positive-predictive value.

<sup>a</sup>McNemar test.

Figure 2. A 63-year-old male with rectal carcinoma. Conventional positron emission tomography (PET) (a), conventional PET/CT fusion (b), point spread function PET (PSF PET) (c) and PSF PET/CT fusion (d) are demonstrated. PSF PET/CT images were sharper and clearer than conventional PET/CT images. The confidence levels in the proximal lymph node (arrows), assessed by two radiologists, were two on conventional images and three on PSF images. Therefore, lymph node metastasis could be diagnosed from PSF images. ROI, region of interest.



stage disease who required neoadjuvant radiotherapy or chemotherapy were excluded. Therefore, the relative lack of progressive nodal involvement in this population would have tended to decrease the diagnostic impact of distant nodal staging using PSF PET/CT. Furthermore, as this study focused on nodal staging in pre-operative cases, the main limitation was the lack of evaluation of other metastases (e.g. liver, lung, bone and peritoneal metastases). Additionally, PET/CT is also useful for diagnosing recurrences of colorectal cancer.<sup>14</sup> In clinical settings

of patients with highly advanced or recurrent colorectal cancers, PSF PET/CT might have a greater diagnostic impact than conventional PET/CT. Additional large-scale prospective studies are needed to clarify the effectiveness of PSF implementation as a diagnostic and prognostic tool. However, the most important issue is that SUV quantification from PSF PET/CT data would depend on reconstruction parameters and different generations of PET systems. In multicentre trials that incorporate SUV, a visual and quantitative analysis of PET data can only be

Table 4. Comparison of conventional positron emission tomography (PET)/CT and point spread function (PSF) PET/CT in the detection of regional and distant lymph node metastasis

	Regional lymph node metastasis		Distant lymph node metastasis	
	Conventional PET/CT	PSF PET/CT	Conventional PET/CT	PSF PET/CT
Sensitivity (%)	53.8	65.3	50.0	83.3
Specificity (%)	96.1	96.1	100.0	100
PPV (%)	93.3	94.4	100.0	100
NPV (%)	67.5	73.5	96.7	98.8
Accuracy (%)	75	80.7	96.8	98.9
<i>p</i> -value	NS ( <i>p</i> = 0.24) <sup>a</sup>		NS ( <i>p</i> = 0.47) <sup>a</sup>	

NPV, negative-predictive value; NS, not significant; PPV, positive-predictive value.

<sup>a</sup>McNemar test.

performed reliably if the PET procedure is standardized. One solution to these problems is to harmonize  $^{18}\text{F}$ -FDG PET quantification. Recently, some multicentre trials have reported reductions in reconstruction-dependent variation by using a harmonizing SUV method.<sup>15,16</sup>

## CONCLUSION

Although when compared with conventional PET/CT, PSF PET/CT did not significantly improve the diagnostic performance of

lymph node staging in patients with colorectal cancer, PSF PET/CT might slightly increase sensitivity without impairing specificity. Additionally, PSF PET/CT is expected to facilitate more confident radiological decisions.

## ACKNOWLEDGMENTS

The authors acknowledge the support of Mr Odasima and Mr Miura, radiological technologists at the Iwate PET Linac Center.

## REFERENCES

- Cohen AM, Tremtterra S, Candela F, Thaler HT, Sigurdson ER. Prognosis of node-positive colon cancer. *Cancer* 1991; **67**: 1859–61.
- Bipat S, Glas AS, Slors FJ, Zwinderman AH, Bossuyt PM, Stoker J. Rectal cancer: local staging and assessment of lymph node involvement with endoluminal US, CT, and MR imaging—a meta-analysis. *Radiology* 2004; **232**: 773–83. doi: <http://dx.doi.org/10.1148/radiol.2323031368>
- Kantorová I, Lipská L, Bělohávek O, Visokai V, Trubač M, Schneiderová M. Routine  $^{18}\text{F}$ -FDG PET preoperative staging of colorectal cancer: comparison with conventional staging and its impact on treatment decision-making. *J Nucl Med* 2003; **44**: 1784–8.
- Panin VY, Kehren F, Michel C, Casey M. Fully 3-D PET reconstruction with system matrix derived from point source measurements. *IEEE Trans Med Imaging* 2006; **25**: 907–21.
- Pichler BJ, Wehrl HF, Judenhofer MS. Latest advances in molecular imaging instrumentation. *J Nucl Med* 2008; **49**(Suppl. 2): 5S–23S. doi: <http://dx.doi.org/10.2967/jnumed.108.045880>
- Lasnon C, Hicks RJ, Beauregard JM, Milner A, Paciencia M, Guizard AV, et al. Impact of point spread function reconstruction on thoracic lymph node staging with  $^{18}\text{F}$ -FDG PET/CT in non-small cell lung cancer. *Clin Nucl Med* 2012; **37**: 971–6. doi: <http://dx.doi.org/10.1097/RLU.0b013e318251e3d1>
- Ozawa Y, Hara M, Shibamoto Y, Tamaki T, Nishio M, Omi K. Utility of high-definition FDG-PET image reconstruction for lung cancer staging. *Acta Radiol* 2013; **54**: 916–20. doi: <http://dx.doi.org/10.1177/0284185113488578>
- Bellevre D, Blanc Fournier C, Switers O, Dugué AE, Levy C, Allouache D, et al. Staging the axilla in breast cancer patients with  $^{18}\text{F}$ -FDG PET: how small are the metastases that we can detect with new generation clinical PET systems? *Eur J Nucl Med Mol Imaging* 2014; **41**: 1103–12. doi: <http://dx.doi.org/10.1007/s00259-014-2689-7>
- Miura K, Odashima S. Usefulness of determining acquisition time by true count rate measure method for delivery  $^{18}\text{F}$ -FDG/PET/CT. [In Japanese]. *Jpn J Radiol Technol* 2016; **72**: 218–26.
- Japanese classification of colorectal carcinoma. Japanese Society for Cancer of the Colon and Rectum. Tokyo, Japan: Kanehara; 2013.
- Kwak JY, Kim JS, Kim HJ, Ha HK, Yu CS, Kim JC. Diagnostic value of FDG-PET/CT for lymph node metastasis of colorectal cancer. *World J Surg* 2012; **36**: 1898–905. doi: <http://dx.doi.org/10.1007/s00268-012-1575-3>
- Yi HJ, Hong KS, Moon N, Chung SS, Lee RA, Kim KH. Reliability of  $^{18}\text{F}$ -fluorodeoxyglucose positron emission tomography/computed tomography in the nodal staging of colorectal cancer patients. *Ann Coloproctol* 2014; **30**: 259–65. doi: <http://dx.doi.org/10.3393/ac.2014.30.6.259>
- Tsunoda Y, Ito M, Fujii H, Kuwano H, Saito N. Preoperative diagnosis of lymph node metastases of colorectal cancer by FDG-PET/CT. *Jpn J Clin Oncol* 2008; **38**: 347–53. doi: <http://dx.doi.org/10.1093/jjco/hyn032>
- Maas M, Rutten IJ, Nelemans PJ, Lambregts DM, Cappendijk VC, Beets GL, et al. What is the most accurate whole-body imaging modality for assessment of local and distant recurrent disease in colorectal cancer? A meta-analysis: imaging for recurrent colorectal cancer. *Eur J Nucl Med Mol Imaging* 2011; **38**: 1560–71. doi: <http://dx.doi.org/10.1007/s00259-011-1785-1>
- Lasnon C, Desmonts C, Quak E, Gervais R, Do P, Dubos-Arvis C, et al. Harmonizing SUVs in multicentre trials when using different generation PET systems: prospective validation in non-small cell lung cancer patients. *Eur J Nucl Med Mol Imaging* 2013; **40**: 985–96. doi: <http://dx.doi.org/10.1007/s00259-013-2391-1>
- Quak E, Le Roux PY, Hofman MS, Robin P, Bourhis D, Callahan J, et al. Harmonizing FDG PET quantification while maintaining optimal lesion detection: prospective multicentre validation in 517 oncology patients. *Eur J Nucl Med Mol Imaging* 2015; **42**: 2072–82. doi: <http://dx.doi.org/10.1007/s00259-015-3128-0>