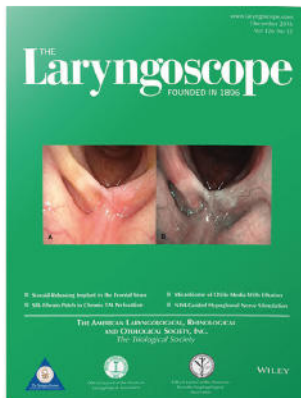



# Premiere Publications from The Triological Society

Read all three of our prestigious publications, each offering high-quality content to keep you informed with the latest developments in the field.




## THE Laryngoscope FOUNDED IN 1896

Editor-in-Chief: Michael G. Stewart, MD, MPH

The leading source for information  
in head and neck disorders.

[Laryngoscope.com](http://Laryngoscope.com)




## Laryngoscope Investigative Otolaryngology Open Access

Editor-in-Chief: D. Bradley Welling, MD, PhD, FACS

Rapid dissemination of the science and practice  
of otolaryngology-head and neck surgery.

[InvestigativeOto.com](http://InvestigativeOto.com)



## ENTtoday A publication of the Triological Society

Editor-in-Chief: Alexander Chiu, MD


Must-have timely information that Otolaryngologist-head and neck surgeons can use in daily practice.

[Enttoday.org](http://Enttoday.org)

WILEY

## ORIGINAL RESEARCH

# Contrast-enhanced ultrasonography for the differential diagnosis of pleomorphic adenomas and Warthin tumors in salivary glands

Daisuke Saito MD<sup>1</sup> | Kiyoto Shiga MD<sup>1</sup>  | Katsunori Katagiri MD<sup>1</sup> |  
Shin-ichi Oikawa MD<sup>1</sup> | Aya Ikeda MD<sup>1</sup> | Kodai Tsuchida MD<sup>1</sup> |  
Jun Miyaguchi MD<sup>1</sup> | Takahiro Kusaka MD<sup>1</sup> | Hidekatsu Kuroda MD<sup>2</sup> |  
Fumiaki Takahashi PhD<sup>3</sup>

<sup>1</sup>Department of Head and Neck Surgery, Iwate Medical University Hospital, Yahaba-cho, Japan

<sup>2</sup>Department of Internal Medicine, Iwate Medical University Hospital, Yahaba-cho, Japan

<sup>3</sup>Division of Medical Engineering, Department of Information Science, Iwate Medical University, Yahaba-cho, Japan

**Correspondence**

Daisuke Saito, Department of Head & Neck Surgery, Iwate Medical University, 2-1-1 Idaidori, Yahaba-cho, Shiwa-gun, Iwate 028-3695, Japan.  
Email: daisaito@iwate-med.ac.jp

**Funding information**

Health Labour Sciences Research Grant; JSPS KAKENHI, Grant/Award Number: 26462619

**Abstract**

**Objective:** Pleomorphic adenomas have risks of malignant transformation and post operate recurrence. Therefore it is important that diagnosing pleomorphic adenomas or Warthin tumors before an operation. We evaluated the usefulness of contrast-enhanced ultrasonography (CEUS) with Sonazoid for making differential diagnoses between pleomorphic adenomas and Warthin tumors.

**Methods:** CEUS was performed the day before surgery in 39 patients. We compared the time-intensity curve and capillary density rate of 14 pleomorphic adenomas and 13 Warthin tumors.

**Results:** Pleomorphic adenomas demonstrated a significantly longer time to peak intensity and lower maximum curve gradient of wash-in than Warthin tumors. The capillary density rate of Warthin tumors tended to be greater than that of pleomorphic adenomas.

**Conclusions:** CEUS and capillary density rate analysis using Sonazoid is helpful for the differential diagnosis of pleomorphic adenomas and Warthin tumors.

**Level of Evidence:** 3b.

**KEYWORDS**

contrast-enhanced ultrasonography, differential diagnosis, pleomorphic adenoma, salivary gland tumor, Warthin tumor

## 1 | INTRODUCTION

Salivary gland tumors account for approximately 5% of all head and neck tumors.<sup>1</sup> Although the majority is usually benign, some might be malignant.<sup>2</sup> Determining whether a benign salivary gland tumor is a pleomorphic adenoma (PMA) or a Warthin tumor (WT) preoperatively

is crucial to select the appropriate surgical procedure. PMAs are known to have a potential of malignant transformation with a 2% to 25% risk, and the surgical procedure such as enucleation make their recurrence rates higher.<sup>3,4</sup> Therefore, at least a partial parotidectomy is recommended as a standard surgical procedure to resect PMAs.<sup>3,4</sup> In contrast, WTs usually do not recur nor undergo malignant

This is an open access article under the terms of the Creative Commons Attribution-NonCommercial-NoDerivs License, which permits use and distribution in any medium, provided the original work is properly cited, the use is non-commercial and no modifications or adaptations are made.

© 2021 The Authors. *Laryngoscope Investigative Otolaryngology* published by Wiley Periodicals LLC on behalf of The Triological Society.

transformation.<sup>5</sup> Therefore, enucleation is a standard surgical procedure for Warthin tumors.

Parotid tumors are usually diagnosed by a combination of clinical findings as well as by imaging and cytological examinations. We can use fine-needle aspiration cytology as a first-line technique for diagnosing salivary gland tumors. Although it is widely used in outpatient clinics, many studies have pointed out its limitations such as a high rate of false-negative results and poor accuracy for distinguishing various types of tumors.<sup>6</sup> As one of the imaging modalities, ultrasonography (US) is more advantageous than computed tomography (CT) or magnetic resonance imaging (MRI) because of its simplicity, low cost, and real-time imaging. Therefore, US is the first-line diagnostic imaging method for assessing salivary gland tumors.<sup>7</sup> Many previous studies have focused on the differential diagnosis between PMAs and WTs using US. However, because of the substantial overlap in ultrasonographic features between these tumors, including the vascular features on Doppler sonography, results were inconsistent between studies.<sup>3,4,8</sup>

Contrast-enhanced ultrasound (CEUS) is a new imaging modality of ultrasound using some kinds of contrast agents and has been applied for the differential diagnosis of salivary gland tumors. CEUS has been extensively explored in recent years and its efficacy has brought a new option in clinical diagnosis.<sup>9</sup> The contrast agent used in ultrasound has special characters; a blood-pool imaging agent without leakage into the interstitial spaces. It is harmless to the kidney and liver.<sup>10,11</sup> Sonazoid (Daiichi Sankyo, Tokyo, Japan), a lipid-stabilized suspension of perfluorocarbon microbubbles, was used in the present study as the ultrasound contrast agent. In Japan, CEUS with Sonazoid is used for the evaluation of liver and mammary gland tumors.<sup>12</sup> The objective of the present study was to evaluate the usefulness of CEUS with Sonazoid for making differential diagnoses between PMAs and WTs.

## 2 | MATERIALS AND METHODS

### 2.1 | Patients

Between July 2015 and June 2018, 39 consecutive patients underwent CEUS examination before surgical excision of salivary gland tumors at the Iwate Medical University. Among them, 14 patients had PMAs on pathologic reports after surgery; 13 had WTs; eight had malignant salivary gland tumors (two salivary duct carcinomas, 2 two malignant lymphomas, one adenocarcinoma, one mucoepidermoid carcinoma, one adenoid cystic carcinoma, and one epithelial myoepithelial carcinoma), while the remaining four had various other benign pathological findings. None of the patients had any serious heart, lung, blood disease, or salivary gland-diffusing disease such as Sjögren syndrome. The present study was approved by the review board of Iwate Medical University Hospital (jRCTs021180035), and written informed consent was obtained from each patient. All procedures followed the ethical standards of the Responsible Committee on Human

Experimentation (institutional and national) and the Declaration of Helsinki (1975), as revised in 2013.<sup>13</sup>

### 2.2 | Ultrasound imaging

CEUS was performed the day before surgery. US was performed using a LOGIQ E9 general imaging system (GE Healthcare, Chicago, Illinois), ML6-15 linear probe (frequency, 6-15 MHz), and a 9L-D linear probe (frequency, 9 MHz) for the evaluation of salivary gland tumors. Before CEUS, B-mode US was performed to examine the slices of target images. All US procedures were performed by the same head and neck surgeon. CEUS imaging was recorded for 2 minutes immediately after a bolus (0.01 mL/kg) injection of Sonazoid. During the US examination, the mechanical index was set at 0.21, the frame rate was set at 19 frames per second, and a dynamic range of 66 dB. The gain, image depth, and transmit focus were optimized for each patient. The cine sequences were saved in the DICOM file format for subsequent analyses.

### 2.3 | Time intensity curve (TIC) analysis

A specific calibration file provided by the vendor for the GE Logiq E9 was used in the analysis software to convert ultrasound images to linearized data for TIC analysis. Regions of interest were drawn manually to avoid the vessels and cystic parts of the tumors. Each region of interest was  $0.5 \times 0.5 \times 3.14 = 0.785 \text{ cm}^2$ . Any motion disturbances or fluctuations by probe shake and respiratory motion of the patients during CEUS were recorded with a motion tracking system. We analyzed the CEUS images in the arterial phase for 100 to 120 seconds after the contrast agent arrived at the target tumor. Three perfusion parameters were extracted from the TICs: time to peak (TTP) intensity, curve gradient of wash-in (Grand), and total area under the TIC (AUC) during wash-in (Figures 1A and 2A).

### 2.4 | Visualization of CEUS

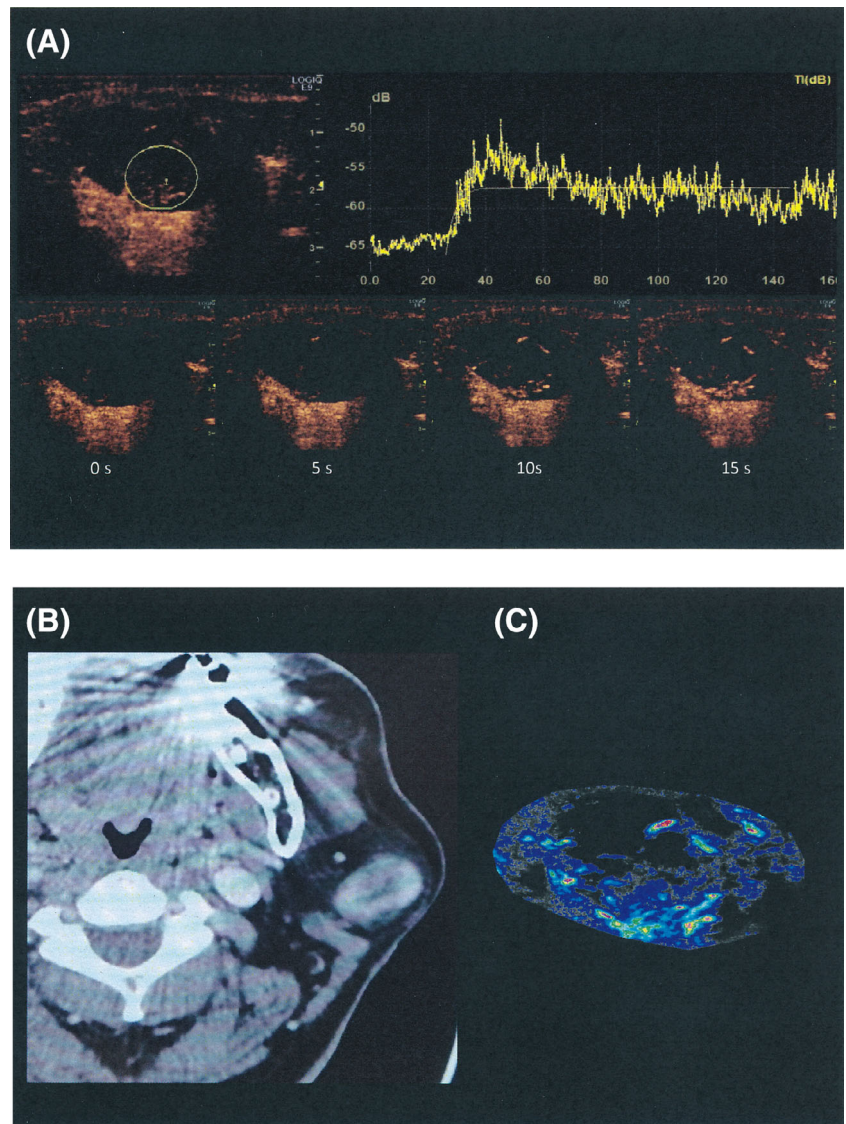
We developed a new image-analyzing software (IwmUltrasonic ver2.00, DITECT, Tokyo) based on an algorithm we previously reported.<sup>14</sup> This software analyzes the video files obtained with CEUS. Visible particles were used to draw accumulated color points, revealing the distribution of capillary vessels. This software can calculate the density of particles in the drawn figures, which is thought to represent the capillary density of the tumor (Figures 1C and 2C).<sup>12</sup> We measured capillary density rates in tumors.

### 2.5 | Statistical analysis

All analyses were conducted using SPSS software (IBM SPSS Statistics 24 for Windows, Advanced Analytics Inc., Tokyo, Japan) and adjusted



**FIGURE 1** A typical case of a 66-years-old man with PMA of the left parotid gland. A, CEUS imaging and TIC analysis. The region of interest was settled within the contrast-enhanced area of the target tumor. B, CT image. The targeted tumor was in the left parotid gland. C, Visualization of CEUS. The capillary density rate was low



by a medical statistician (F.T.). For all statistical analyses, 2-tailed  $P < .05$  was considered statistically significant.

### 3 | RESULTS

The 27 salivary gland tumors were classified into two groups: the PMA group (14 cases) and the WT group (13 cases). Table 1 shows the characteristic features of these two groups. Twenty-three tumors were in the parotid gland, and four were in the submandibular glands. Of the patients with PMAs, eight were male and six were female, and the mean age was 62.1 (range, 47-74 years). Of the patients with WTs, all were male, and the mean age was 65.9 years (range, 58-81 years). The diameters of the tumors were measured using US images. The mean long diameter of the PMSs was 33.6 (range, 16-75) mm and short diameter was 35.6 (range, 10-60) mm. The mean long diameter of WTs was 35.6 (range, 22-59) mm and short diameter was 22.2 (range, 10-37) mm (Table 1). Statistical analyses were performed

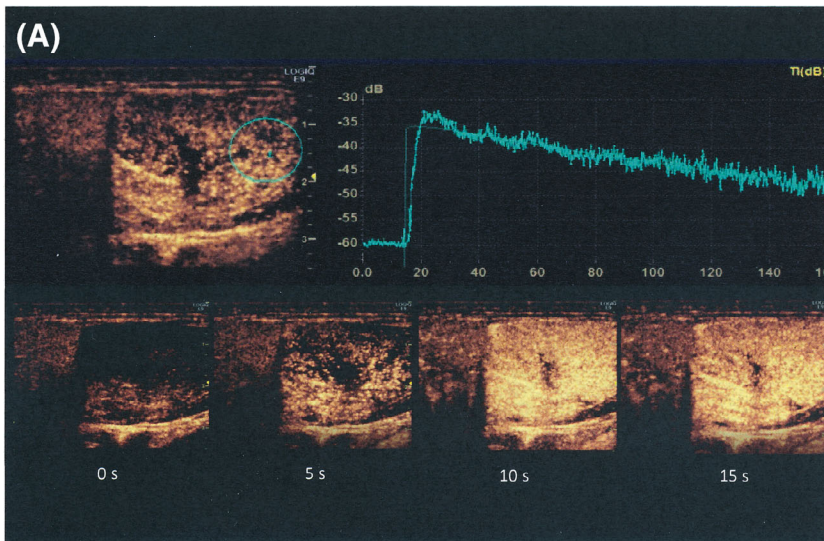
using the  $t$  test to compare the quantitative parameters of the TIC and the capillary density between the two tumor groups.

#### 3.1 | Findings of TIC

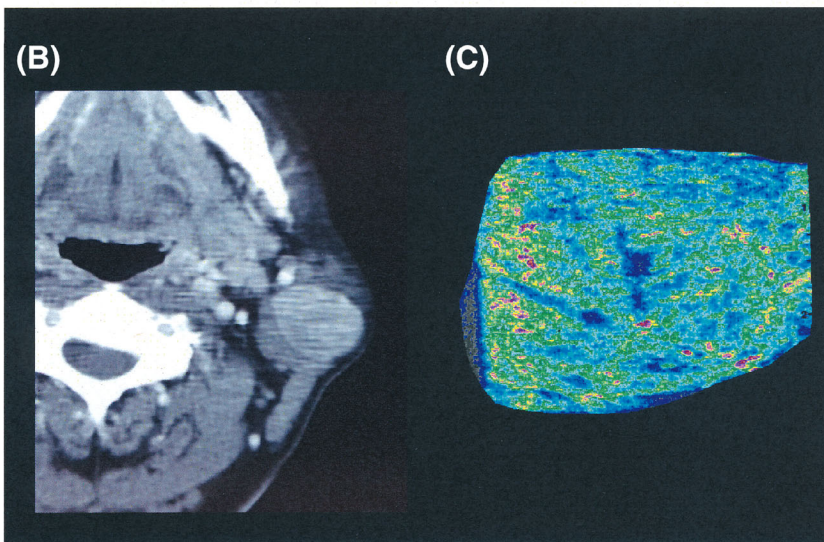
The means of TTP were 17.95 seconds in PMA and 10.99 seconds in WT ( $P = .003$ ). Means of Grand were 1.06 in PMA and 1.90 in WT ( $P = .011$ ). The means of AUC were 996.47 at PMA and 1326.99 at WT ( $P = .19$ ). TTP and Grand showed significant differences (Figures 3 and 4), whereas AUC showed no significant differences (Figure 5).

#### 3.2 | Findings of capillary density

The means of capillary density rate were 43% in PMA and 55.8% in WT ( $P = .285$ ). Although capillary density seemed to be larger in WT, there was no significant difference between PMA and WT.



**FIGURE 2** A typical case of a 63-years-old man with WT's of the bilateral parotid glands. We focused on the left parotid gland tumor. A, CEUS imaging and TIC analysis. The region of interest was settled within the contrast-enhanced area of the target tumor. B, CT image. The targeted tumor was in the left parotid gland. C, Visualization of CEUS. The capillary density rate was high

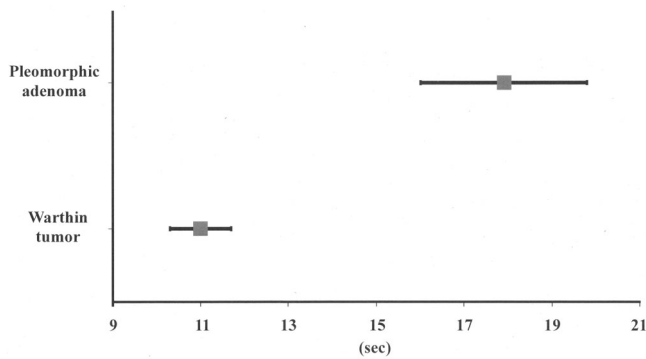


	Pleomorphic adenomas (n = 14)	Warthin tumors (n = 13)	P value
Age (years)	Mean 62.1	Mean 65.9	.16 <sup>a</sup>
Sex			
Male	8	13	.0074 <sup>b</sup>
Female	6	0	
Tumor site			
Parotid gland	10	13	.037 <sup>b</sup>
Submandibular gland	4	0	
Size, mm			
Long diameter (mm)	Mean 33.6	Mean 23.1	.7 <sup>a</sup>
Short diameter (mm)	Mean 35.6	Mean 22.2	.83 <sup>a</sup>

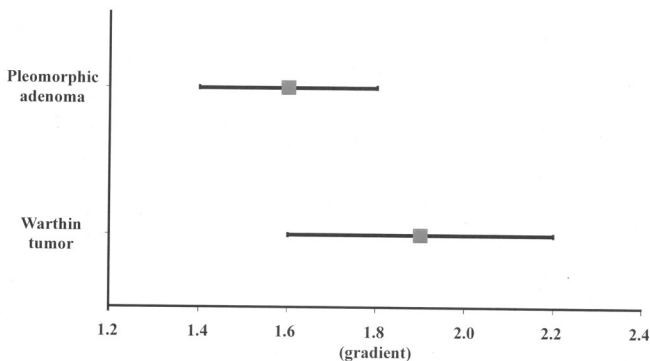
**TABLE 1** Characteristics of patients and their tumors

<sup>a</sup>t test.

<sup>b</sup> $\chi^2$  test.



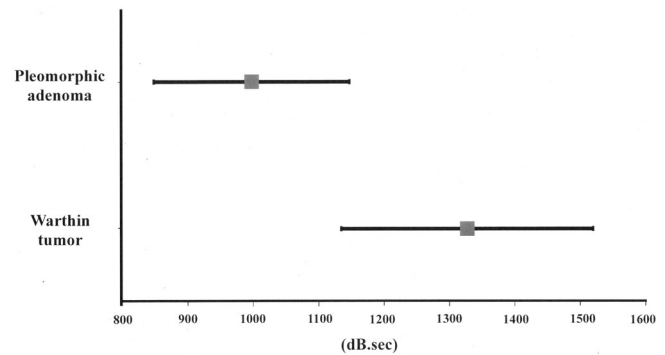
**FIGURE 3** Time to peak (TTP) intensity analysis. TTP values were obtained from each time-intensity curve (TIC) of the tumors and plotted on the graph. The squares represent means, while the lines through the square represent the SEMs (standard error mean). There was a significant difference between these two groups ( $P = .003$ )



**FIGURE 4** The curve gradient of wash-in (Grad) analysis. Grad values were obtained from each time-intensity curve (TIC) of the tumors and plotted on the graph. The squares represent the means, while the lines through the square represent the SEMs. There was a significant difference between these two groups ( $P = .011$ )

### 3.3 | Diagnostic accuracy of other diagnostic modalities

In preoperative fine needle aspiration cytology, 9 of 14 cases of PMAs and 4 of 13 cases of WTs showed accurate results compared with the pathological diagnoses of surgically removed specimens. In the radiologist's report of contrast-enhanced computed tomography, 4 of 12 cases of PMAs and 2 of 13 cases of WTs showed accurate results, when compared with the pathological diagnoses. In the radiologist's report of contrast-enhanced magnetic resonance imaging, 4 of 13 cases of PMAs and none of the 11 cases of WTs showed accurate results when compared with the pathological diagnoses. In the color Doppler ultrasound (CDUS) diagnosis, we evaluated the images of these tumors using vascularity grades proposed by Rong et al.,<sup>4</sup> where we assumed that PMTs were Grade 0 or 1 and WTs were Grade 2 or 3. Nine of 14 cases of PMAs and 8 of 13 cases of WTs were accurately diagnosed. In CEUS, when we set a cut-off value of TTP (14.2 seconds) and assumed that tumors with TTP >14.2 seconds



**FIGURE 5** The total area under the TIC (AUC) during wash-in analysis. AUC values were obtained from each time-intensity curve (TIC) of the tumors and plotted on the graph. The squares represent the means, and the lines through the square represent the SEMs. There was no significant difference between the two groups ( $P = .19$ )

**TABLE 2** Diagnostic accuracy of ultrasound modalities to distinguish pleomorphic adenomas from Warthin tumors

	CDUS	CEUS
Sensitivity (%)	64	71
Specificity (%)	62	92
Positive predictive value (%)	64	91
Negative predictive value (%)	62	75

Abbreviations: CDUS, color Doppler ultrasonography; CEUS, contrast-enhanced ultrasonography.

were PMAs, and those with TTP <14.2 seconds were WTs. Ten of 14 cases of PMAs and 12 of 13 cases of WTs showed accurate diagnoses compared with the pathological diagnoses. In this study, the sensitivity, specificity, positive predictive value, and negative predictive value of PMAs from WTs of CEUS (71%, 92%, 91%, and 75%, respectively) were better than those of CDUS (64%, 62%, 64%, and 62%, respectively) (Table 2).

## 4 | DISCUSSION

US has been used for the differential diagnosis of benign and malignant breast tumors. In addition, CEUS using Sonazoid has been confirmed to be superior to unenhanced US for the differential diagnosis of these breast tumors. Enhancement patterns of benign lesions included a strong homogeneous enhancement of the entire lesion, weak homogeneous enhancement of the entire lesion, or no enhancement of the entire lesion. Enhancement patterns that were diagnostic of malignant lesions included heterogeneous enhancement without apparent defects, heterogeneous enhancement with apparent defects, and enhancement extending outward beyond the expected border of the lesion.<sup>15</sup> On the other hand, as for the parotid tumors, there have been many studies focusing on differential diagnosis between PMAs



and WTs using US previously. Miao et al. reported that the ratio of the long diameter to the short diameter of tumors was useful for differentiating PMAs from WTs. Isoechogenicity was present only in PMAs and was specific for those tumors.<sup>8</sup> However, other studies found no significant differences in diameter and echogenicity between PMAs and WTs.<sup>3,4,16</sup>

Rong X et al. reported that there were more frequent cystic areas present in WTs than in PMAs.<sup>4</sup> However, Miao et al. reported that there was no significant difference in the presence of cystic areas among the tumor types.<sup>8</sup> Therefore, it is controversial whether many grayscale sonographic features are useful for differentiating PMAs from WTs.

Inseon et al. reported that vascular distributions and internal vascularity on power Doppler sonography and microvascular sonography were all significantly different. Most PMAs showed avascular patterns and most WTs showed central or mixed vascularity. Most PMAs had no internal vascularity at all, whereas more than half of WTs had moderate to marked internal vascularity. They concluded that diagnostic accuracy of grayscale sonography with microvascular sonography was higher than that of grayscale sonography with power Doppler sonography.<sup>16</sup> All US were performed by expert head and neck neuroradiologists. This study divided and compared vascular patterns and internal vascularity into four grades. Therefore, specialized knowledge and expertise were required for accurate interpretation of the images.

Jia-mei et al. reported that CEUS was useful for differentiating PMAs from WTs. Their TICs showed that PMAs were hypovascularized with poor perfusion, whereas WTs and malignant tumors were hypervascularized with rich perfusion. Additionally, malignant tumors showed significantly shortened TTP and a richer maximum signal intensity compared with WTs.<sup>9</sup> In our study, TTP and Grand showed significant differences between PMA and WT. However, there was no significant difference between WT and malignant tumors. Ultrasound is an operator-dependent examination, so it is critical that we provide objective parameters for a more accurate examination. The former study used TICs with a small region of interest (0.1 cm<sup>2</sup>). Setting a small ROI has the risk of creating a large diversity of data. A TIC with a small ROI can be a less objective examination, and it is difficult to provide reproducible data. In our study, we evaluated tumor tissue using TIC analysis with a large region of interest (0.79 cm<sup>2</sup>) and performed an examination with high objectivity and reproducibility (Figures 1A and 2A). Furthermore, our visualization of the CEUS technique can easily express capillary density (Figures 1C and 2C). Although there was no significant

difference between PMA and WT, this method offers a promising alternative for the differential diagnosis of PMA and WT by medical staff without expertise.

As expected, diagnostic modalities such as CT or MRI do not have enough power to make differential diagnoses of salivary gland tumors, especially PMAs and WTs. In fact, interpretation by the expert radiologist showed a low positive predictive value for the diagnosis of PMAs and WTs (Table 3). Although fine needle aspiration biopsy showed relatively high sensitivity, its accuracy rates were approximately two-thirds and one-third of PMAs and WTs, respectively. Recently, the mechanical and technological development of CDUS has been rapid, and its diagnostic efficacy for salivary gland tumors, using vascularity grades, has been high. However, the sensitivity, specificity, positive predictive value, and negative predictive value of CEUS were superior to those of CDUS (Table 2). In addition, our study also revealed that clarifying histopathological differences and differences in vascular construction enables the accurate and appropriate diagnosis of parotid tumors such as PMAs and WTs. We concluded that CEUS could be an essential diagnostic modality for the diagnosis of PMAs and WTs.

This study has some limitations. First, the sample size was small. Larger-scale prospective clinical studies are needed to confirm these findings. Second, CEUS has not yet been authorized for salivary gland tumor evaluation in our country.

## 5 | CONCLUSION

The evaluation of the tumor bloodstream by CEUS is a simple, safe, and noninvasive examination for patients that can be performed conveniently in real-time and could help differentiate PMA from WT in salivary glands. It is critical for surgeons to know the accurate diagnosis preoperatively to select a right method to treat the salivary gland tumors.

## ACKNOWLEDGMENTS

This work was supported by a Grant-in-aid for JSPS KAKENHI Grant Number 26462619 and Health Labour Sciences Research Grant. We would like to thank Editage (www.editage.com) for English language editing.

## CONFLICT OF INTEREST

The authors have no conflicts of interest to declare.

## ORCID

Kiyoto Shiga  <https://orcid.org/0000-0002-7461-1352>

## BIBLIOGRAPHY

1. MacHugh JB, Visscher DW, Barnes EL. Update on selected salivary gland neoplasms. *Arch Pathol Lab Med*. 2009;133:1763-1774.
2. Assili S, Fathi KA, Aghaghazvini L, Saligheh RHR, Pirayesh IJ. Dynamic contrast magnetic resonance imaging (DCE-MRI) and diffusion weighted MR imaging (DWI) for differentiation between benign and malignant salivary gland tumors. *J Biomed Phys Eng*. 2015;5:157-168.

**TABLE 3** Comparison of sensitivity of each diagnostic modality

	FNA	CT	MRI
PMA			
Sensitivity (%)	64	33	31
WT			
Sensitivity (%)	31	15	0

Abbreviations: CT, contrast-enhanced computed tomography; FNA, fine needle aspiration cytology; MRI, contrast-enhanced magnetic resonance imaging.

3. Yuan WH, Hsu HC, Chou YH, Hsueh HC, Tseng TK, Tiu CM. Gray-scale and color Doppler ultrasonographic features of pleomorphic adenoma and Warthin's tumor in major salivary glands. *Clin Imaging*. 2009;33:348-353.
4. Rong X, Zhu Q, Ji H, Li J, Huang H. Differentiation of pleomorphic adenoma and Warthin's tumor of the parotid gland: ultrasonographic features. *Acta Radiol*. 2014;55:1203-1209.
5. Shimizu M, Ussmuller J, Hartwein J, Donath K, Kinukawa N. Statistical study for sonographic differential diagnosis of tumorous lesions in the parotid gland. *Oral Surg Oral Med Oral Pathol Oral Radiol Endod*. 1999; 88:226-233.
6. Salgarelli AC, Cappare P, Bellini P, Collini M. Usefulness of fineneedle aspiration in parotid diagnostics. *Oral Maxillofac Surg*. 2009;13: 185-190.
7. Petrovan C, Nekula DM, Mocan SL, Voidăzan TS, Coșarcă A. Ultrasonography-histopathology correlation in major salivary glands lesions. *Rom J Morphol Embryol*. 2015;56:491-497.
8. Miao LY, Xue H, Ge HY, Wang JR, Jia JW, Cui LG. Differentiation of pleomorphic adenoma and Warthin's tumour of the salivary gland: is long-to-short diameter ratio a useful parameter. *Clin Radiol*. 2015;70: 1212-1219.
9. Jia-mei G, Qin C, Quing Z, Ying-xian L. Quantitative diagnosis of salivary gland tumors with contrastenhanced ultrasound – preliminary study. *Oral Surg Oral Med Oral Pathol Oral Radiol*. 2013;116:784-790.
10. Marotti J, Heger S, Tinschert J, et al. Recent advances of ultrasound imaging in dentistry: a review of the literature. *Oral Surg Oral Med Oral Pathol Oral Radiol*. 2013;115:819-832.
11. Quaia E. Microbubble ultrasound contrast agents: an update. *Eur Radiol*. 2007;17:1995-2008.
12. Oikawa S, Shiga K, Saito D, Katagiri K. Association between contrast-enhanced ultrasonography and histopathological findings of the metastatic lymph nodes of patients with head and neck cancer: a preliminary study. *Oncol Lett*. 2018;15:4171-4176.
13. World Medical Association. World medical association declaration of Helsinki: ethical principles for medical research involving human subjects. *JAMA*. 2013;310:2191-2194.
14. Ito K, Noro K, Yanagisawa Y, et al. High-accuracy ultrasound contrast agent detection method for diagnostic ultrasound imaging systems. *Ultrasound Med Biol*. 2015;41:3120-3130.
15. Miyamoto Y, Ito T, Takada E, Omoto K, Hirai T, Moriyasu F. Efficacy of sonazoid (perflubutane) for contrast enhanced ultrasound in the differentiation of focal breast lesions: phase 3 multicenter clinical trial. *AJR Am J Roentgenol*. 2014;202:W400-W407.
16. Inseon R, Sangil S, Young HL, et al. Vascular pattern analysis on microvascular sonography for differentiation of pleomorphic adenomas and Warthin tumors of salivary glands. *J Ultrasound Med*. 2018; 37:613-620.

**How to cite this article:** Saito D, Shiga K, Katagiri K, et al. Contrast-enhanced ultrasonography for the differential diagnosis of pleomorphic adenomas and Warthin tumors in salivary glands. *Laryngoscope Investigative Otolaryngology*. 2021;1-7. <https://doi.org/10.1002/lio2.565>