

症 例

A case of carcinoma of the lower alveolus and gingiva in which ^{18}F FDG-PET was useful for assessing the therapeutic effects of concurrent intraarterial chemoradiotherapy

Hideki HOSHI, Hiroyuki NAKATANI, Yoshiki SUGIYAMA,

Hideyuki FURUUCHI, Takemitsu SAWADA, Osamu IGARASHI*

Second Department of Oral and Maxillofacial Surgery, School of Dentistry, Iwate Medical University

(Chief : Prof. SUGIYAMA Yoshiki)

*Department of Dentistry and Oral Surgery, Mutsu General Hospital

(Chief : Dr. IGARASHI Osamu)

[Received : February 14, 2007 ; Accepted : March 19, 2007]

Abstract : For some time, we have performed concurrent intraarterial chemoradiotherapy for functional and morphological conservation in the treatment of oral cancer and have reported its usefulness. However, one of the disadvantages associated with concurrent therapy is difficulty in assessing post-therapeutic effects. Hence, since 1993, we have used positron emission tomography with 2 - deoxy- 2 - fluoro [^{18}F]-D-glucose (^{18}F FDG-PET) for the assessment of therapeutic effects. Here, we report a patient with carcinoma of the lower alveolus and gingiva in whom ^{18}F FDG-PET was performed to assess the effects of the present concurrent therapy and post-therapeutic recurrence and metastasis. In this patient, functional and morphological conservation was achieved, and post-therapeutic QOL was favorable.

The patient was a 50-year-old woman who was diagnosed with squamous cell carcinoma of the lower alveolus and gingiva and was brought to our department to undergo therapy. At the initial visit, ^{18}F FDG-PET showed 50-minute and 60-minute SUV (standardized uptake value) of 12.35 ± 0.10 and 13.89 ± 0.49 , respectively, thus confirming an increase in SUV. After admission, the superficial temporal artery was cannulated, and 3-drug chemotherapy [bleomycin (total dose: 60 mg), methotrexate (total dose: 200 mg) and cisplatin (total dose: 100 mg)] and radiotherapy (Linac, total dose: 40.25 Gy) were performed. After the concurrent therapy, the tumor shrunk and disappeared clinically, and ^{18}F FDG-PET did not show a clear increase (50-minute value: 3.30 ± 0.15 ; 60-minute value: 3.58 ± 0.14). Hence, because a complete response (CR) was achieved, surgery could be avoided, and maintenance therapy was performed. At 2 years and 6 months after the end of the concurrent therapy, ^{18}F FDG-PET showed low SUV (50-minute value: 1.91 ± 0.16 ; 60-minute value: 1.90 ± 0.02). So far, there has been no sign of recurrence or metastasis, and the clinical course has been favorable.

Key words : ^{18}F FDG-PET ; concurrent intraarterial chemoradiotherapy ; oral cancer ; carcinoma of the lower alveolus and gingiva

Introduction

In the treatment of oral cancer, it is necessary to thoroughly consider functional and morphological conservation. During

functions such as mastication, deglutition, and articulation, the mandible performs various motor functions with the surrounding soft tissue, and it is also a bone that defines the contours of the lower face

and plays an important role in maintaining the location and morphology of soft tissue. Therefore, mandibular defects caused by surgery lead to marked dysfunction, and measures against such defects are closely related to post-therapeutic QOL^{1,2)}. At our department, we have reported the usefulness of concurrent intraarterial chemoradiotherapy for functional and morphological conservation^{3~7)}. One of the problems associated with this concurrent therapy is difficulty in assessing post-therapeutic effects. Therefore, since 1993, we have investigated the assessment of therapeutic effects by functional diagnostic imaging based on position emission tomography using 2 - deoxy - 2 - fluoro [^{18}F]-D-glucose (^{18}F FDG-PET)^{8~11)}.

In this report, we present a patient with T4N0M0 carcinoma of the lower alveolus and gingiva undergone concurrent intraarterial chemoradiotherapy and was then assessed with ^{18}F FDG-PET to evaluate therapeutic effects and post-therapeutic recurrence and metastasis. Surgery was not performed during the primary treatment, and functional and morphological conservation led to favorable post-therapeutic QOL.

Case Report

A-50-year woman was referred to our hospital because of persistent wound

caused by tooth extraction. On June 18, 2001, she experienced tooth mobility and pain, and third molar was extracted by a dentist. Because the pain persisted and gingival swelling was confirmed, anti-inflammatory agents were administered and second molar was extracted. However, because the symptoms did not improve, she was referred to the department of dentistry and oral surgery of a general hospital on August 28. On September 7, diagnostic cytology and biopsy confirmed squamous cell carcinoma. The patient was referred to our department.

At our first examination, the patient had a medium build, and her nutritional state was favorable. Her complexion was healthy, but her facial configuration was asymmetrical. In the left gonial angle, a diffuse tumor and pressure pain were confirmed. Desensitization was absent in the left mental region and lower lip, however, mouth opening was restricted to 18 mm. As to the submandibular lymph nodes, one node as large as the tip of the thumb was palpable on the left side and one the size of a soybean was palpable on the right side. Both nodes were soft, elastic, and mobile, and findings indicative of metastasis were absent. No cervical lymph nodes were palpable. With regard to oral findings, from the buccal alveolar region to the buccal mucosa of second molar and third molar, redness and swelling were confirmed. The extraction

A case of carcinoma of the lower alveolus and gingiva in which ^{18}F FDG-PET was useful for assessing the therapeutic effects of concurrent intraarterial chemoradiotherapy

Hideki HOSHI, Hiroyuki NAKATANI, Yoshiki SUGIYAMA,

Hideyuki FURUUCHI, Takemitsu SAWADA, Osamu IGARASHI*

Second Department of Oral and Maxillofacial Surgery, School of Dentistry, Iwate Medical University

*Department of Dentistry and Oral Surgery, Mutsu General Hospital

1 - 3 - 27 Chuo-dori, Morioka, Iwate 020-8505, Japan

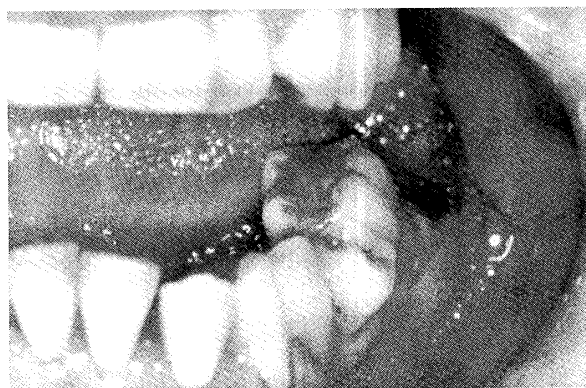

Fig. 1. Oral findings at the first examination. The extraction socket of second molar and third molar was about 20×20 mm size and was mildly concave. The bottom of socket had a fine granular appearance and was friable.

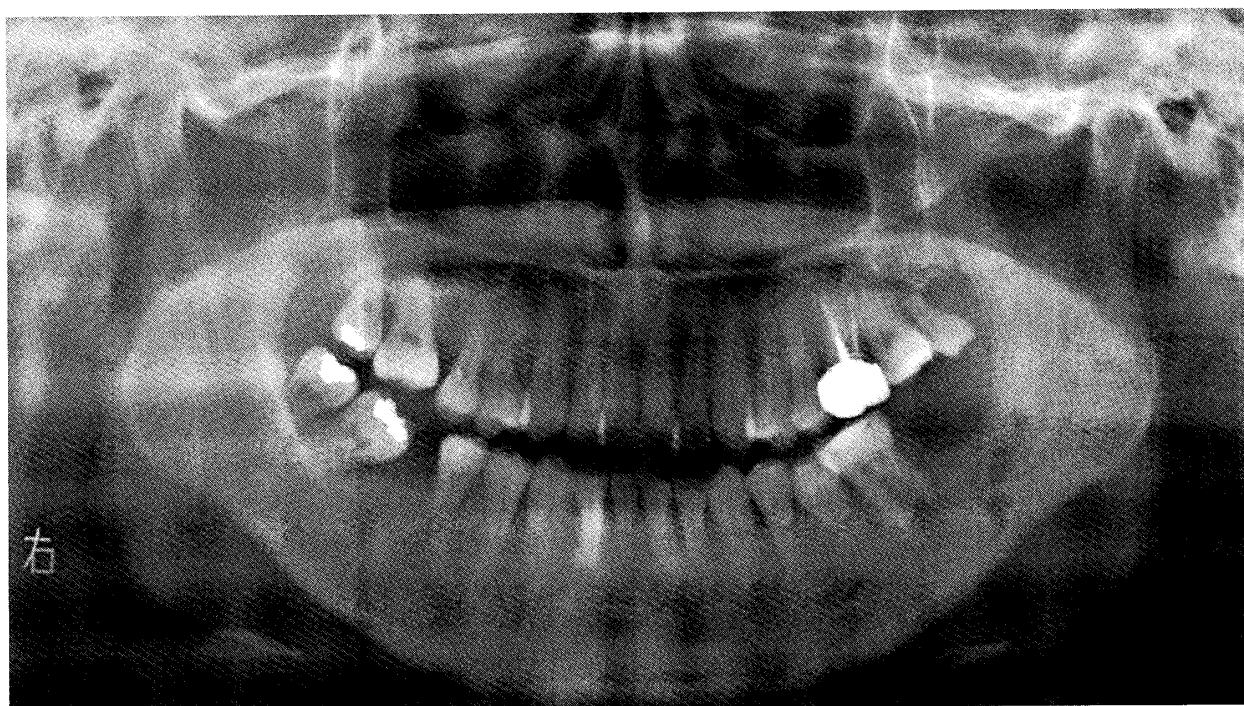


Fig. 2. Panoramic radiography at the first examination. A panoramic radiography showed bone resorption with irregular borders mostly around the extraction socket and from first molar to the mandibular ramus, and resorption reached the inferior margin of the mandible in the some areas.

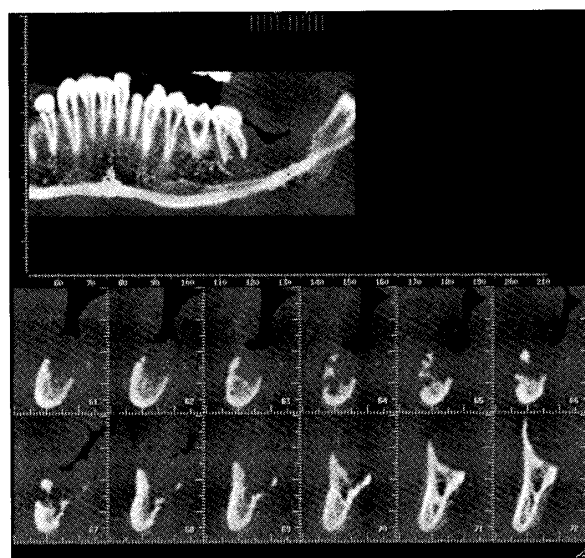

Fig. 3. Dental Multi Planar Reconstruction (Dental MPR) image at the first examination. Dental MPR image showed destruction of the buccal and lingual cortical bone and resorption of the upper wall of the mandibular canal.

socket of second molar and third molar was about 20x20 mm in size and was mildly concave. The bottom of the socket had a fine granular appearance and was friable (Fig. 1). Induration was also palpable around the lesion. With regard to imaging findings at the initial visit, panoramic radiography showed bone resorption with irregular borders mostly around the extraction socket and from first molar to the mandibular ramus, and resorption reached the inferior margin of the mandible in some areas (Fig. 2). Dental MPR showed destruction of the buccal and lingual cortical bone and loss of the upper wall of the mandibular canal (Fig. 3).

On September 17, 2001, the patient was admitted to undergo various medical examinations. On September 25, because biopsy had confirmed squamous cell carcinoma at the referring institution (Fig. 4), the left superficial temporal artery was cannulated, under local anesthesia. The tip of the catheter was inserted into the main branch of the lateral carotid artery, slightly medial to the bifurcation with the facial artery. Two courses of 3-drug chemotherapy using bleomycin (BLM), methotrexate (MTX), and cisplatin (CDDP) (hereinafter referred to as BMP therapy) were performed (Fig. 5). The total doses of BLM, MTX, and CDDP were 60, 200, and 100

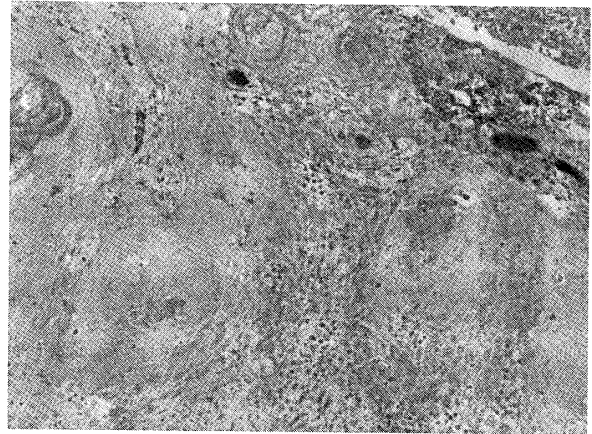


Fig. 4. Pathologic findings. (H-E stain. $\times 100$)

mg, respectively. A total of 40.25 Gy radiotherapy was administered using a Linac X-ray generator (1.15 Gy per treatment, two treatments per day, 35 fractionated irradiation). Although first molar was within the tumor, it was extracted after the start of chemotherapy but before the start of radiotherapy, in order to avoid tooth movement stimulating the tumor. After the end of BMP therapy and radiotherapy, mild concavity was seen in the area corresponding to the extraction socket, but the surface was smooth, and findings indicative of residual tumor were absent. Hence it was thought that a complete response (CR) was obtained. The results of ^{18}F FDG-PET performed at this time showed a standardized uptake value (SUV) of 3.30 ± 0.15 at 40-50 minutes and 3.58 ± 0.14 at 50-60 minutes (Fig. 6). No clear increase

Medicine	Dose	Method of administration	Days of administration														
			1	2	3	4	5	6	7	8	9	10	11	12	13	14	15
BLM	5 mg/body	one shot i.a.	↓	↓	↓										↓	↓	↓
MTX	50mg/body	24 hours continuous i.a.			↓												↓
CDDP	10mg/body	24 hours continuous i.a.						↓	↓	↓	↓	↓					

i.a. : intraarterial administration

Fig. 5. Schedule of 3-drug (BLM : bleomycin, MTX : methotrexate, CDDP : cisplatin) chemotherapy. One course includes BLM (5 mg/body/day) given in 20 min. daily from day 1 to 3 and day 13 to 15, MTX (50 mg/day/body) given continuously for 24 hours daily from 3 and 15, and CDDP (10 mg/body/day) given continuously for 24 hours daily from day 6 to 10.

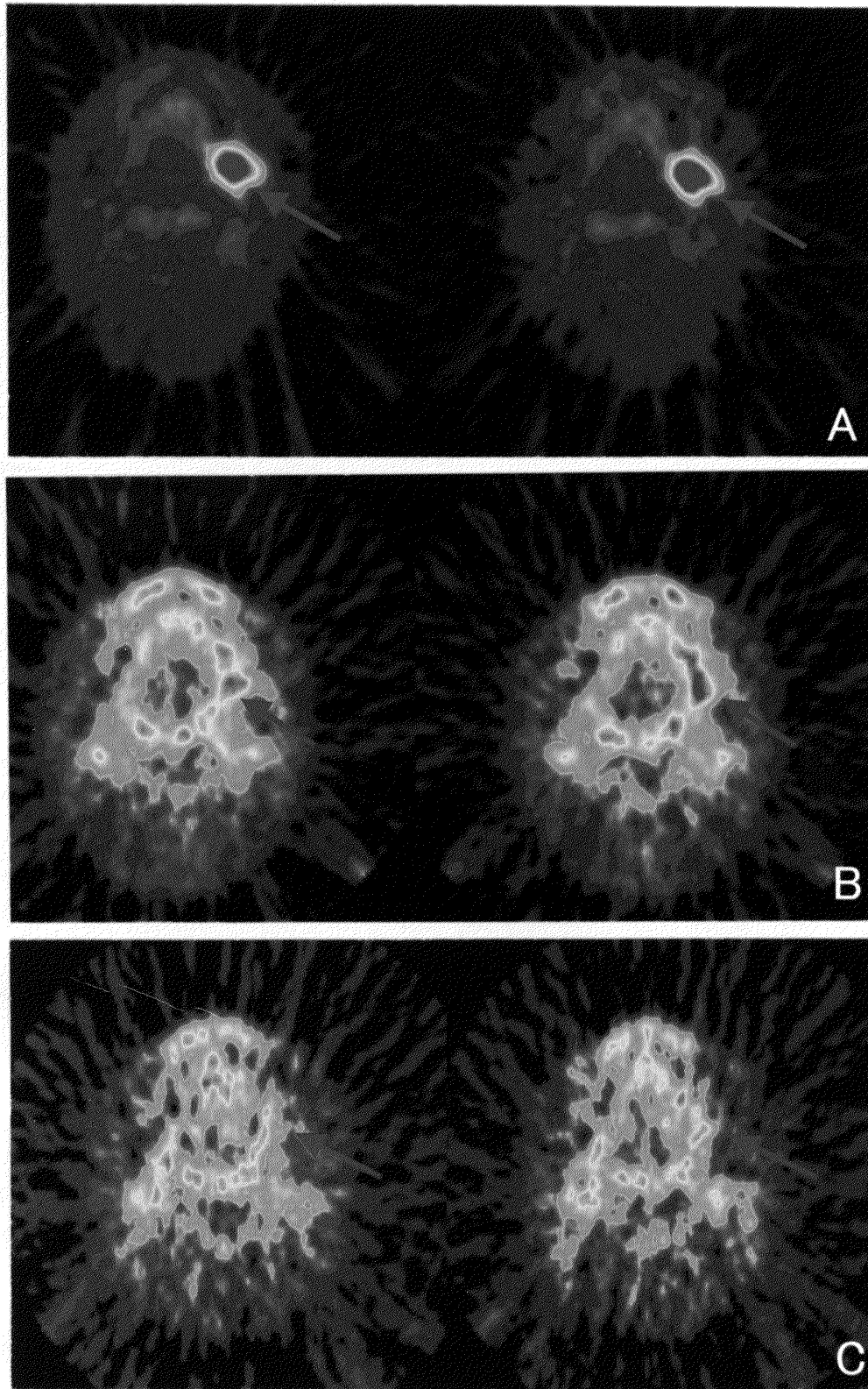


Fig. 6. ^{18}F -FDG-PET axial cut image.

A : At the first examination. The SUVs of the primary lesion were 12.35 ± 0.10 at 40-50 minutes and 13.80 ± 0.49 at 50-60 minutes. Increase was seen clearly. B : At the end of concurrent therapy. The SUVs of the primary lesion were 3.30 ± 0.15 at 40-50 minutes and 3.58 ± 0.14 at 50-60 minutes. No clear increase was seen. C : After 2 years and 6 months since the end of concurrent therapy. The SUVs of the primary lesion were 1.91 ± 0.16 at 40-50 minutes and 1.90 ± 0.02 at 50-60 minutes. An increase had not been seen.

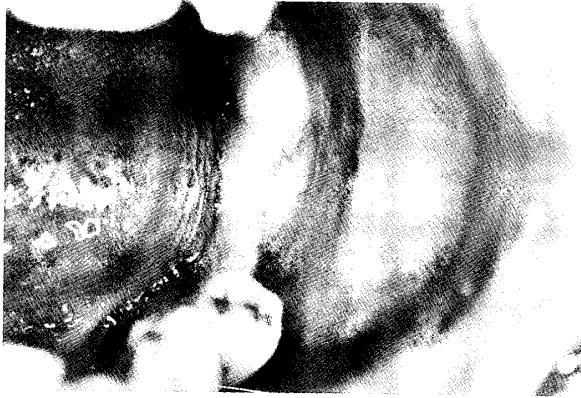

Fig. 7. Oral findings after 2 years and 6 months since the end of concurrent therapy.

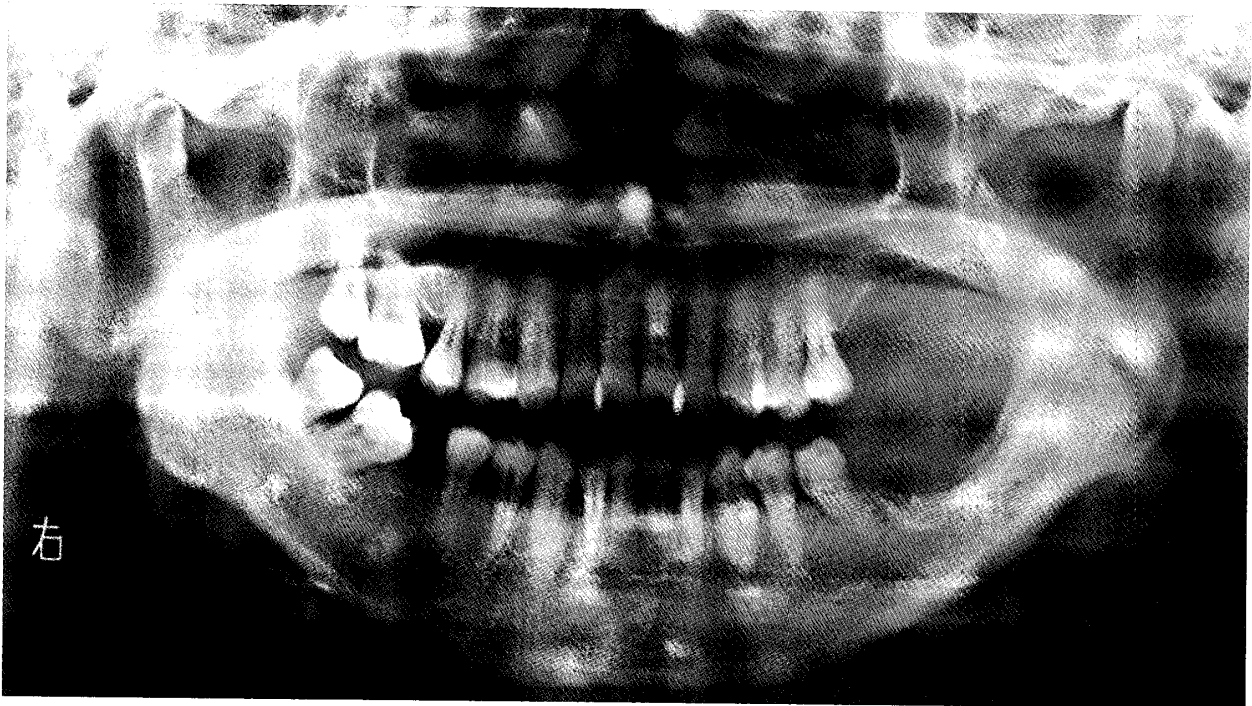


Fig. 8. Panoramic radiography after 2 years and 6 months since the end of concurrent therapy.

was seen. Consequently, we believed that the tumor had disappeared, and decided to administer outpatient maintenance therapy without surgery. Various investigations were used during follow-up, and ^{18}F FDG-PET performed 2 years and 6 months after the end of concurrent therapy showed low SUV (50-minute value: 1.91 ± 0.16 ; 60-minute value: 1.90 ± 0.02). An increase has not been seen, and so far, signs of recurrence or metastasis have not been confirmed. The clinical course of the patient has been favorable. At present, she has mild dry mouth, but has no functional or esthetic compromise or

impaired activities of daily living (Fig. 7, 8).

Discussion

Because the functions that are directly related to activities of daily living are concentrated around the oral region, functional and morphological conservation greatly influences QOL following oral cancer therapy^{1, 2)}各.

At our department, to achieve functional and morphological conservation, concurrent intraarterial chemoradiotherapy has been performed for the treatment of oral cancer^{3~7)}. In the treatment of carcinoma of

the lower alveolus and gingiva, if CR is achieved by this concurrent therapy, surgery is not performed during primary therapy, and maintenance therapy is performed for functional and morphological conservation. The 5-year-survival for such cases has been favorable at 81.2%^{4, 5)}.

The disadvantages associated with the present concurrent therapy are difficulty in assessing therapeutic effects and dry mouth. As far as the assessment of therapeutic effects is concerned, we have been performing not only CT and MRI, but also functional diagnostic imaging using ¹⁸FDG-PET since 1993^{8~12)}. ¹⁸FDG-PET is a technique based on increased glucose metabolism by malignant tumors^{8, 13, 14)}. Like glucose, ¹⁸FDG is absorbed by tumors, and after phosphorylation, it is accumulated in tumor cells. Consequently, an area with increased glucose metabolism can be visualized. Quantitative assessment of ¹⁸FDG accumulation is carried out based on SUV. As to the assessment of therapeutic effects, basic studies conducted at our department have indicated that SUV clearly increases in tumor tissue at more than 40 minutes after intravenous administration of ¹⁸FDG⁸⁾. As a result, assessment is based on the change of 40-60 minute SUV. The change of SUV is assessed in three grades: "decreased" and "unchanged", indicating tumor disappearance, and "increased", indicating residual tumor^{8, 9)}. This assessment is used for therapeutic planning^{9~11)}.

Like stomatitis with or without dry mouth is seen in during therapy in almost all patients. However, treatment of dry mouth is difficult, and there is currently no effective solution. Dry mouth is being treated palliatively by gargling or using

mouthwash, ointment, gel, artificial saliva and medication. It is necessary to establish an effective measure against dry mouth to improve QOL.

In the present patient, CR was achieved clinically, and ¹⁸FDG-PET findings did not show a clear increase, thus suggesting that the tumor had disappeared.

Based on the above findings, we determined that it would be possible to avoid performing surgery during primary therapy, and maintenance therapy was performed. So far, the patient has been monitored using various medical examinations including ¹⁸FDG-PET, but signs of recurrence or metastasis have not been seen. Although the patient still suffers from mild dry mouth, favorable findings have been obtained in terms of function and esthetics, and her post-therapeutic QOL is satisfactory.

Conclusion

A patient with carcinoma of the lower alveolus and gingiva (T4M0N0) underwent concurrent intraarterial chemoradiotherapy, and functional diagnostic imaging using ¹⁸FDG-PET was useful for assessing therapeutic effects and observing post-therapeutic course.

Acknowledgment

This work was supported, in part by a Grant-in-Aid for High-Tech Research Project (2005-2009) from the Ministry of Education, Culture, Sports, Science and Technology of Japan.

References

- 1) Shimizu, M., Kohama, G., editors. : Oral Cancer. 1st ed., Dental Diamond Co., Tokyo Japan, pp

- 442-457, 1989.
- 2) Yoshidumi, T., Satake, B., Uruma, T., Katori, H., Ukai, J., Ueda, K. : Mandibular resection for oral and oropharyngeal cancer. *Head and Neck Cancer* 25 : 413-420, 1999.
 - 3) Fukazawa, H., Sekiyama, S., Yanagisawa, T. : New intraarterial combination chemotherapy using bleomycin, methotrexate and cisplatin with simultaneous radiotherapy in oral cancer. *Oncologia* 21 : 108-111, 1988.
 - 4) Yonemochi, T. : Histopathological studies of radiation-combined intra-arterial chemotherapy on squamous cell carcinoma of the mandible. *Dent. J. Iwate Med. Univ.* 21: 14-28, 1996.
 - 5) Yonemochi, T., Sekiyama, S., Hoshi, H., Sugiyama, Y., Misawa, H., Sasamori, M., Obata, K. : Clinical study of combined treatment with radiotherapy and intra-arterial chemotherapy for squamous cell carcinoma of the mandibular gingival. *Jpn. J. Oral Maxillofac. Surg.* 44 : 841-851, 1998.
 - 6) Hoshi, H. : Clinical and Histopathological studies on the squamous cell carcinoma of the tongue treated with radiation-combined intra-arterial chemotherapy. *Dent. J. Iwate Med. Univ.* 25 : 292-306, 2000.
 - 7) Nakasato, T., Katoh, K., Sone, M., Ehara, S., Tamakawa, Y., Hoshi, H., Sekiyama, S. : Superselective continuous arterial infusion chemotherapy through the superficial temporal artery for oral cavity tumors. *Am. J. Neuroradiol.* 21 : 1917-1922, 2000.
 - 8) Funaki, K. : Evaluation of tumor activity using 2-deoxy-2-¹⁸F fluoro-D-glucose. *Dent. J. Iwate Med. Univ.* 19 : 47-53, 1994.
 - 9) Funaki, K., Hoshi, H., Namiki, H., Sugiyama, Y., Sekiyama, S. : Evaluation of therapeutic effects and prognosis for malignant tumors of the oral cavity by positron emission tomography (PET). *Head and Neck Cancer* 27 : 132-137, 2001.
 - 10) Hoshi, H., Sekiyama, S., Shibasaki, M., Funaki, K., Misawa, H., Satoh, M. : A case of carcinoma of the lower alveolus and gingival with a combination of intra-arterial infusion chemotherapy and radiotherapy without mandibulectomy. - Evaluation of the therapeutic effect by ¹⁸F-DG-PET - . *J. Jpn. Soc. Oral Tumor* 14 : 23-29, 2002.
 - 11) Namiki, H., Sekiyama, S., Hoshi, H., Furuuchi, H., Takeda, Y., Nakasato, T. : A case of carcinoma of the tongue treated with a combination of intra-arterial infusion chemotherapy and radiotherapy. . *J. Jpn. Soc. Oral Tumor* 15 : 205-211, 2003.
 - 12) Nakasato, T., Hoshino, M., Izumisawa, M., Kuroda, T., Katoh, K., Sone, M., Ehara, S., Hoshi, H., Sekiyama, S. : MRI evaluation of carcinoma of the tongue after superselective continuous arterial infusion chemotherapy combined with radiotherapy. *J. J. Clinical Radiol.* 49 : 445-780, 2004.
 - 13) Okamura, T., Kawabe, J., Koyama, K., Kobashi, T., Sakamoto, H., Tsuyuguchi, N., Jomura, N., Shimonishi, Y., Kishimoto, K., Yamada, R., Nakai, Y., Ochi, H. : Differentiation between malignant and benign head and neck lesions using SUV and time course of SUV on ¹⁸F-FDG PET study. *J. J. Clinical Radiol.* 41 : 1487-1493, 1996.
 - 14) Shozushima, M., Terasaki, K. : Positron emission tomography (PET) for oncologic applications in oral region. *Dent. J. Iwate Med. Univ.* 29: 213-223, 2004.

動注，放射線同時併用療法後の ^{18}F FDG-PET による 治療効果判定が有用であった下顎歯肉癌の 1 例

星 秀樹，中谷 寛之，杉山 芳樹，古内 秀幸，澤田 剛光，五十嵐 修*

岩手医科大学歯学部口腔外科学第二講座

(主任：杉山 芳樹 教授)

*むつ総合病院歯科・口腔外科

(主任：五十嵐 修 部長)

(受付：2007年2月14日)

(受理：2007年3月19日)

要旨：当科では，従来から機能温存，形態温存を目的に抗癌剤の動脈内投与と放射線療法との同時併用療法を行い，その有用性を報告してきた。しかし，そのなかで治療後の治療効果判定の困難さが問題点として残された。そこで1993年から 2 -deoxy- 2 -fluoro [^{18}F]-D-glucose を用いた positron emission tomography (^{18}F FDG-PET) による治療効果判定を加え検討を行っている。今回は，下顎歯肉癌に対して本療法後， ^{18}F FDG-PET による治療効果判定および治療後の再発，転移の診断に用い，一次治療時に外科療法を回避し，機能温存，形態温存が可能となり治療後の QOL の向上が得られた経過良好な 1 例を経験したので報告する。

患者は50歳女性で，下顎歯肉扁平上皮癌 (T4N0M0) と診断され，治療目的に当科を紹介来院した。初診時の ^{18}F FDG-PET の所見では，腫瘍放射能比 (standardized uptake value, SUV) は50分値 12.35 ± 0.10 ，60分値 13.89 ± 0.49 と上昇を認めた。入院後，浅側頭動脈カニューレーションを行い，bleomycin(総量60mg)，methotrexate(総量200mg)およびcisplatin(総量100mg)の3剤併用化学療法と放射線療法 (Linac 総量40.25Gy) を行った。治療後臨床的に腫瘍は縮小，消失し， ^{18}F FDG-PET による所見でも SUV は50分値 3.30 ± 0.15 ，60分値 3.58 ± 0.14 と明らかな上昇は認めず CR と判定し，この結果，外科療法を行わず，維持療法を行った。治療後2年6か月後に行った ^{18}F FDG-PET による所見でも SUV は50分値 1.91 ± 0.16 ，60分値 1.90 ± 0.02 と低値を示し，現在まで，再発，転移の徴候はなく，経過良好である。

キーワード： ^{18}F FDG-PET，動注放射線同時併用療法，口腔癌，下顎歯肉癌