

## A case report of periodontal therapy for a patient with severe periodontitis

Takashi YAEGASHI and Kazuyuki UYENO

Department of Periodontology, School of Dentistry,  
Iwate Medical University

(Deputy chief : Associate Prof. Michinobu SUGAWARA)

[Received : April 30, 2002 ; Accepted : May 23, 2002]

**Abstract :** Periodontal therapy for severe periodontitis seems to be different from that for slight or moderate periodontitis. It is indispensable for preserving teeth with severe alveolar resorption to finish adequate initial treatment and to carry out periodontal surgery for complete elimination of the inflammation surrounding the teeth as soon as possible. Orthodontic treatment is often required in case of diastema and extreme maxillary protrusion associated with severe periodontitis. In addition, the cases with narrow attached gingiva sometimes need free gingival graft or apically positioned flap surgery. This is the report for periodontal therapy of a severe periodontitis patient with orthodontic treatment and free gingival graft. At first examination, many teeth seemed to be difficult to preserve, however the most of all were preserved for about 9 years. Through this case, we recognized that periodontal therapy for severe periodontitis required various treatment different from periodontal therapy for slight or moderate periodontitis.

**Key words :** severe periodontitis, periodontal therapy, free gingival graft

### Introduction

Periodontal therapy for severe periodontitis seems to be different from that for slight or moderate periodontitis. Initial treatments for such severe cases often require occlusal adjustment, temporary splint and endodontic treatment and so forth. In addition, filling with hydroxylapatite<sup>1,2)</sup>, mucogingival surgery<sup>3,4)</sup> such as free gingival graft, guided tissue regeneration (GTR)<sup>5)</sup> and orthodontic treatment<sup>6,7)</sup> are also frequently performed in the severe cases after the initial treatment.

This is the report for a periodontal severe case with orthodontic treatment and free gingival graft.

### Case report

A 42-year-old female visited our hospital (Dental department of Iwate Medical University Hospital) with main complaints of diastema at anterior areas. Oral hygiene control of this patient was not good at first visit. Intraoral examination revealed redness and swelling at the gingiva of upper and lower incisors particularly (Fig. 1), and probing pocket depth was almost 6-8 mm

---

A case report of periodontal therapy for a patient with severe periodontitis  
Takashi YAEGASHI and Kazuyuki UYENO  
Department of Periodontology, School of Dentistry, Iwate Medical University,  
1-3-27 Chuo-dori, Morioka, Iwate 020-8505, Japan




Fig. 1. Intraoral findings of first medical examination.  
Diastema and protrusion were obviously observed at anterior areas.

at many sites with bleeding and pus discharge. Moderate or severe resorption of alveolar bone were revealed as a whole by radiographic examination (Fig. 2). There were a large bone defect and furcation involvement around the roots of molar teeth. This case was diagnosed as chronic periodontitis (adult periodontitis) owing to the association of plaque and others.

Scaling and root planning, temporary splint (wire resin splint), occlusal adjustment and endodontic treatment for the anterior teeth were immediately started as initial treatment. Periodontal surgery containing apically positioned flap surgery

and frenectomy were carried out at the area after reevaluation of initial treatment sites. Root separation and resection were performed at molar sites during periodontal surgery. Orthodontic treatment for the anterior teeth was started after molar fixation (Fig. 3 a, b) in corrective phase. The permanent restoration of the anterior teeth for fixation were carried out after improvement of the teeth position and direction by the orthodontic treatment (Fig. 3 c, d). In spite of adaptation with apically positioned flap surgery<sup>3,4)</sup>, attached gingiva was narrow in lower incisors. Therefore, free gingival graft was performed in these areas after total fixation (Fig. 4 a-d). Other areas such as lower molar sites similarly required the graft because of the narrow attachment, but the graft was not carried out yet. Maintenance care was carried out at 2 or 3 months intervals. At these visits the patient was reinstructed oral hygiene procedure particularly on the treated areas. About 9 years after first examination, the periodontal condition of the treated area was almost healthy (Fig. 5). Radiograph at that time revealed the alveolar bone condition was almost improved in

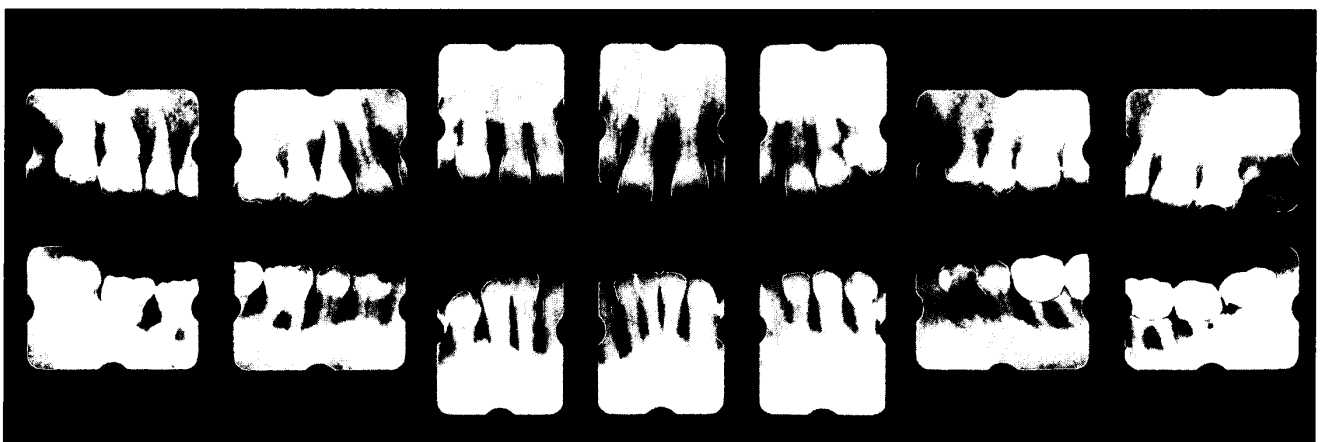

Fig. 2. X-ray findings at first medical examination.  
Moderate or severe bone resorption induced by periodontitis were observed as a whole.

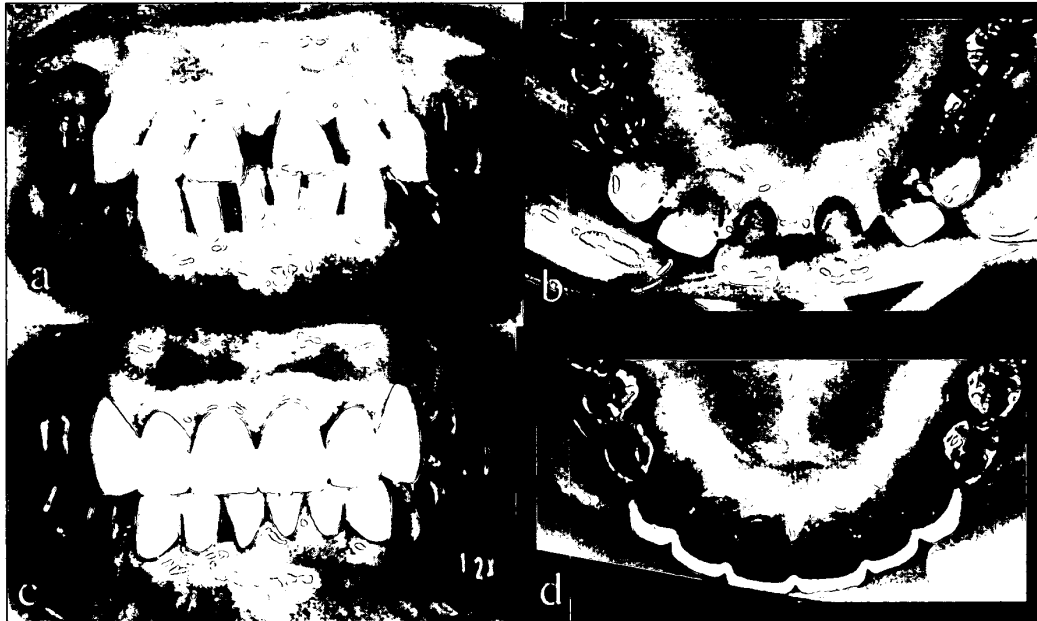

Fig. 3. Before orthodontic treatment and after permanent fixation at anterior areas.  
 a : Intraoral findings before the anterior teeth movement.  
 b : Occlusal findings of the maxillary anterior areas before the movement.  
 c : Intraoral findings after the permanent fixation.  
 d : Occlusal findings after the maxillary fixation.

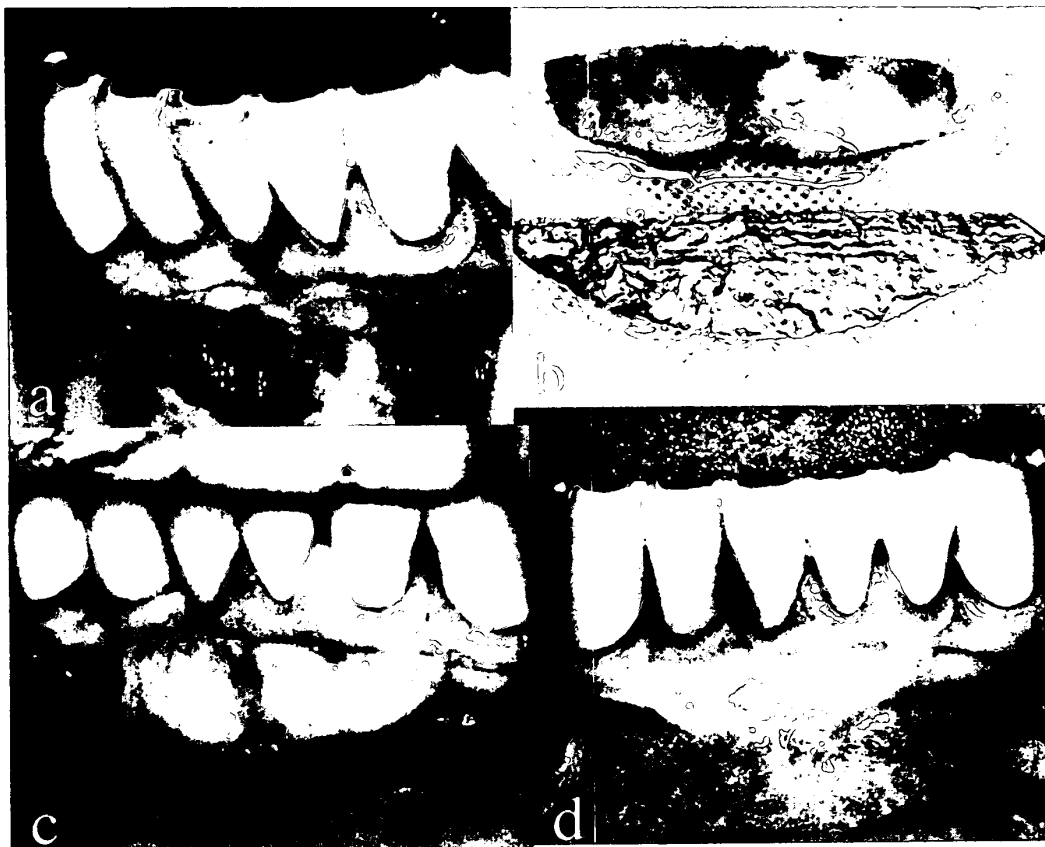

Fig. 4. Step photo findings of free gingival graft.  
 a : Preparation of a recipient site for free gingival graft.  
 b : Graft from donor site and tinfoil template of desired graft.  
 c : Graft transferred.  
 d : After 6 month, showing widened zone of attached gingiva.

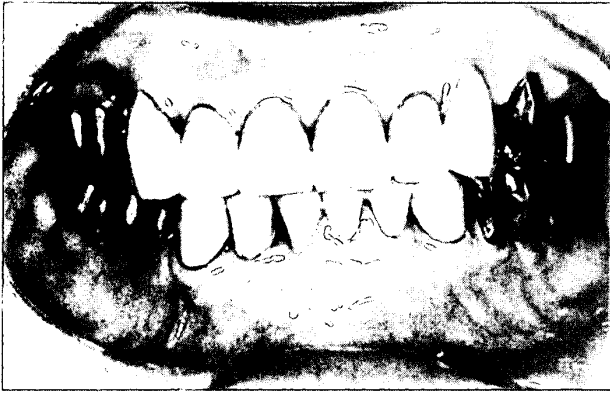


Fig. 5. Intraoral findings at about 9 years after first medical examination. Problems of periodontal condition was not observed particularly.

comparison with Fig. 2 and Fig. 6.

### Discussion

Periodontal therapy for a patient with severe periodontitis is particularly difficult for a general dentist. In order to preserve the severe teeth, we think that a general dentist as soon as possible should ask an advise of periodontal profession who has much experience. In this case, many teeth seemed to be difficult to preserve at first examination (Fig. 1,2) about 9 years ago, but the most of all were preserved for a long time until now (Fig. 5,6). In order to preserve such periodontal severe teeth, immediate

surgical treatment seemed to be necessary. If the destruction of the alveolar bone around the teeth make rapid progress beyond the apex during medical examination and initial treatment, it is impossible to preserve the teeth absolutely owing to lack of periodontal ligament cells for periodontal tissue regeneration<sup>2,5)</sup>. We thought the period from first medical examination to periodontal surgery was one of the most important factors for preservation in such teeth.

Several times in periodontal severe cases, width of attached gingiva after periodontal surgery is too narrow to keep maintenance care. Because the keratinized gingival tissues are often sacrificed for pocket elimination by the periodontal surgery. The width of the attached gingiva in this case also was narrow in spite of application of apically positioned flap surgery<sup>3,4)</sup>. So, free gingival graft was performed in the areas (Fig. 4). The width of attached gingiva after pocket elimination is very important particularly in severe cases.

Malocclusion is often observed in periodontal severe cases. Particularly, diastema, deep overbite and extreme

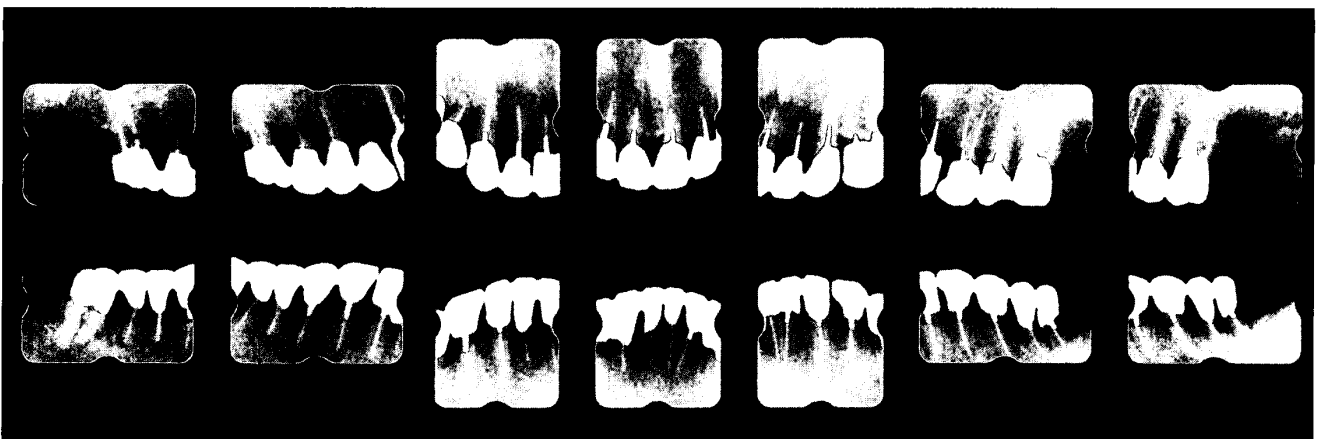


Fig. 6. X-ray findings at about 9 years after first medical examination. Improvement of alveolar bone level and the condition was observed in comparison with Fig. 2 at first visit.

maxillary protrusion are frequently associated with progress of severe periodontitis. Orthodontic treatments<sup>6,7)</sup> for such cases are important as well as periodontal therapy in order to acquire a good occlusal relationship. In this case, the orthodontic treatment was carried out at anterior areas. After the treatment, permanent fixation was performed for ideal occlusion (Fig. 3).

This periodontal severe case showed that periodontal therapy for severe periodontitis is different from that for slight or moderate lesions. We concluded that early pocket elimination by periodontal surgery, obtaining proper width of attached gingiva and suitable orthodontic treatment were important factor for the teeth preservation of severe periodontitis.

**Acknowledgements :** This work was supported, in part, by a Grant-in-Aid for Scientific Research (A-13307059 and High

Performance Biomedical Materials Research) from the Ministry of Education, Science, Sports and Culture of Japan.

### References

- 1) Lekovic, V., Kenney, E.B., Carranza, F.A. Jr. and Danilovic, V.: Treatment of class II furcation defects using porous hydroxylapatite in conjunction with a polytetrafluoroethylene membrane. *J Periodontol.* 61 : 575–578, 1990.
- 2) Yaegashi, T.: Effect of hydroxylapatite particles during healing of experimental furcation involvement in beagle dogs. *J. Jpn. Soc. Periodontol.* 31 : 83–99, 1989.
- 3) Ramfjord, S.P. and Ash, M.M.: *Periodontology and Periodontics: Modern Theory and Practice.* Ishyaku EuroAmerica, Inc. St. Louis, pp 305–325, 1989.
- 4) Carranza, F.A.: *Glickman's clinical periodontology.* 7 th ed., W.B. Saunders Co., Philadelphia, pp 875–908, 1990.
- 5) Wilson, T.G. and Kornman, K.S.: *Fundamentals of Periodontics.* Quintessence Publishing Co., pp 408–411, 1996.
- 6) Geiger, A. and Hirschfeld L.: *Minor tooth movement in general practice.* Third ed., The C. V. Mosby Co., St. Louis, pp106–107, 532–535, 1974.
- 7) Kieser, J.B.: *Periodontics: A Practical Approach,* Wright, London, pp 343–361, 1990.

## 高度歯周炎症例の歯周治療

八重柏 隆, 上野 和之

岩手医科大学歯学部歯科保存学第二講座

(主任代理：菅原 教修 助教授)

(受付：2002年4月30日)

(受理：2002年5月23日)

抄録：高度歯周炎に罹患した患者の歯を保存するためには、軽度から中等度歯周炎症例の歯周治療とは異なり、適切な初期治療と可能な限り速やかな歯周外科処置が欠かせないと思われる。また歯周炎の進行にともなう歯の離開や突出が生じる高度例では、矯正処置を必要とする。さらに付着歯肉が不足する症例では遊離歯肉移植術等を余儀なくされる場合も多い。我々は、歯の移動および遊離歯肉移植術を必要とした高度歯周炎罹患症例の治療例を報告する。初診段階では保存困難と思われた歯が多数存在したが、約9年間にわたりその大多数を保存することができた。今回の治療を通じて、高度歯周炎症例の歯周治療では、軽度から中等度歯周炎症例とは異なり、いろいろな処置が必要とされることをあらためて認識した。

キーワード：高度歯周炎, 歯周治療, 遊離歯肉移植