

Title: Effects of wearing and removing dentures on oropharyngeal motility during swallowing

Short title: Dentures and pharyngeal swallowing

Article category: Original Research

Authors: Shohei Onodera¹, Junichi Furuya², Hisanori Yamamoto¹, Yasushi Tamada¹, Hisatomo Kondo¹

¹Department of Prosthodontics and Oral Implantology, School of Dentistry, Iwate Medical University, Morioka, Japan.

²Department of Oral Health Care Science for Community and Welfare, Graduate School of Medical and Dental Sciences, Tokyo Medical and Dental University, Bunkyo-ku, Japan.

Corresponding author: Dr. J. Furuya; Department of Oral Health Care Science for Community and Welfare, Graduate School of Medical and Dental Sciences, Tokyo Medical and Dental University, 1-5-45 Yushima, Bunkyo-ku, Tokyo 113-8549, Japan
Email: furuyajunichi@gmail.com

Title: Effects of wearing and removing dentures on oropharyngeal motility during swallowing

Short title: Dentures and pharyngeal swallowing

Article category: Original Research

Authors: Shohei Onodera¹, Junichi Furuya², Hisanori Yamamoto¹, Yasushi Tamada¹, Hisatomo Kondo¹

Affiliation: ¹Department of Prosthodontics and Oral Implantology, School of Dentistry, Iwate Medical University, Morioka, Japan.

²Department of Oral Health Care Science for Community and Welfare, Graduate School of Medical and Dental Sciences, Tokyo Medical and Dental University, Bunkyo-ku, Japan.

Corresponding author: Dr. J. Furuya; Department of Oral Health Care Science for Community and Welfare, Graduate School of Medical and Dental Sciences, Tokyo Medical and Dental University, 1-5-45 Yushima, Bunkyo-ku, Tokyo 113-8549, Japan

Email: furuyajunichi@gmail.com

Abstract

Background: Wearing dentures and dysphagia are common in older individuals, however, it is still unknown how dentures affects oral and pharyngeal swallowing.

Objectives: The purpose of this study was to reveal the effects of wearing and removing dentures on oropharyngeal movements during pharyngeal swallowing in the feeding sequence of solid food.

Methods: Participants were 25 edentulous volunteers (9 men, 16 women; mean age 76.2 years) who wore complete dentures. The test food was minced agar jelly containing barium sulfate.

Subjects were instructed to feed and swallow the test food with or without dentures during observation using videofluorography. We quantitatively evaluated the range, distance, and duration of oropharyngeal movements during pharyngeal swallowing.

Results: When dentures were absent, the range of mandible and hyoid movements were significantly expanded in the anterosuperior direction, and the range of laryngeal movement was significantly expanded in the anterior direction. Additionally, the posterior pharyngeal wall contraction and upper esophageal sphincter opening significantly increased. In addition, the distances of the mandible, hyoid, and laryngeal movements, and the mandibular duration were significantly extended when dentures were absent. No significant differences were observed in the duration of movements of other organs between wearing and removing dentures.

Conclusions: The hyoid bone, larynx, posterior pharyngeal wall, and upper esophageal sphincter do not change their duration of movements when dentures were removed, but rather, expand their

range of movement. This might be spatial change of oropharyngeal movement to avoid temporal changes in pharyngeal swallowing when dentures were absent in edentulous older individuals.

Keywords: Aging, dentures, dysphagia, mastication, swallowing.

Introduction

Oral intake is closely related to nutrition and quality of life, and feeding and swallowing functions in older individuals have a strong, direct influence on their health and well-being.^{1,2} Decline of feeding and swallowing function in older individuals is caused not only by primary diseases, such as stroke and neurological diseases, but also by age-related changes.³ This decline also occurs in cases of edentulism owing to age-related oral changes and dental disease.^{4,5} After the loss of many teeth, recovery of oral function through the use of complete dentures is often necessary in these individuals.⁶ Therefore, elucidation of the relation between the feeding and swallowing functions and the use of complete dentures is an important issue facing aging societies.

To date, most studies concerning dentures and oral functions have focused only on mastication. In recent years, however, dysphagia in older individuals has become an important social problem.³ Moreover, as the close relation between the oral cavity and the pharynx has been elucidated from functional and anatomical viewpoints,⁷ several studies elucidated the relation between dentures and swallowing function in older individuals. Among them, a cross-sectional study was begun to clarify the relation between edentulism and dysphagia and the relation between denture use and the improvement of swallowing function.⁵ Furthermore, a physiological study revealed that the use of complete dentures has beneficial effects on swallowing. Wearing dentures could decrease the risk of laryngeal penetration,⁸ stabilize swallowing movements,⁹ stabilize tongue-palate contact,¹⁰ shorten bolus pharyngeal transit time,^{11,12} and improve bolus transport dynamics.¹³ However, most

of previous studies focused on liquid swallowing, and there were few study focused on swallowing during feeding and swallowing of solid food. It is partially revealed that liquid swallowing differ from swallowing during feeding solid food,¹⁴ suggesting that the influence of denture wearing on swallowing may change as Yamamoto et al.¹³ previously reported about the influence on bolus transportation.

Wearing complete dentures by edentulous individuals can, in particular, allow the recovery of oral anatomical structures and lost occlusal support, maintaining oral and pharyngeal anatomical morphology correctly.¹⁵ Yoshikawa et al.⁹ reported that the range of lingual movement during liquid swallowing became unstable under conditions of no dentures, and Kondoh et al.¹⁰ also reported that swallowing function has been improved by wearing dentures as a result of recovering tongue-palate contact in edentulous older individuals. These studies suggested that changes in the oral anatomical structures due to removing and wearing dentures functionally influence oral tongue movements during liquid swallowing. However, the detail influence on pharyngeal movements during feeding solid food were not still elucidated. Thus, in the present study, we observed pharyngeal swallowing during feeding solid food in older edentulous individuals when wearing complete dentures (CD) and with no dentures (ND). We particularly attempted to elucidate the effects of wearing dentures on movements of the mandible, hyoid bone, larynx, posterior pharyngeal wall, and upper esophageal sphincter.

Materials and methods

Participants

The study included 25 edentulous volunteers aged more than 65 years (9 men, 16 women; mean age 76.2 ± 8.5 years \pm SD) who became completely edentulous for a minimum of 1 year. They have worn complete dentures newly made at Iwate Medical University Hospital Dental Center and who were found to have had a favorable course at 3 months following delivery of the dentures, and hoped to examine their swallowing function. Subjects who presented with signs of severe dysphagia associated with a generalized condition were excluded. The study protocols were approved by the ethics committee of the Iwate Medical University School of Dentistry (No. 01150), which conformed to the principles described in the World Medical Association Declaration of Helsinki. All participants provided written consent to participate in the study after the principal aim, methods, benefits, and detriments of the present study were sufficiently explained orally and in writing.

Observation of feeding and swallowing

Feeding and swallowing of test food was observed based on settings used in a previous study.¹³

For this reason, we omit the details concerning videofluoroscopic study of swallowing and preparation of the test food. Participants sat in a 90° position in a wheelchair equipped with a videofluoroscopy device (VF Style VF-MT-2; Tomei Brace Co., Aichi, Japan). We placed lead balls

on the tragus and neck of participants as a calibration indicator for motion analysis. The test food was the same as our previous research,¹³ and we described the texture of test food briefly. The test food consisted of minced agar jelly containing 40% barium sulfate with a particle diameter of 4.0–5.6 mm, and the texture of test food was adjusted so that participants could masticate and swallow it with dentures and could manage to feed and swallow without dentures. We observed the participants feeding and swallowing the test food (1) when wearing complete upper and lower dentures (CD) and (2) when wearing no dentures (ND). The patients' oropharyngeal parameters were randomly recorded three times (a total of six tests) under each condition after sufficient practice. The videos were recorded at 30 frames per second. The test food was placed on the tongue using a spoon, and participants were instructed to feed and swallow as usual, which means the easiest way to feed and swallow for them with or without dentures as they usually do. Therefore, we did not order the number of mastication until swallowing and the timing of the swallowing.

Motion analysis of feeding and swallowing movements

Motion analysis software (Dipp-Motion V version 1.1.23; DITECT, Tokyo, Japan) was used to analyze the video recorded for videofluoroscopic study of swallowing, and all video frames during the initial pharyngeal swallowing after bolus transportation to the pharynx were analyzed. The five oral and pharyngeal measurement points were tracked according to the origin and reference

planes as shown in Fig. 1: mandible, hyoid bone, larynx, posterior pharyngeal wall (PPW), and upper esophageal sphincter (UES). As shown in Fig. 2, we defined the observation period of their movements during pharyngeal swallowing according to process model,¹⁴ and tracked them automatically and manually. We then calculated the duration, distance, and range of movements after correcting the actual image values through calibration. With regard to range of movement, as shown in Fig. 3, we calculated the trajectory of movement of each measurement point and measured the horizontal range of the x-axis and vertical range of the y-axis. The ranges of PPW and UES movements were measured only in the horizontal direction because vertical movement was almost entirely absent. Finally, we calculated the mean values as the typical individual values for CD and ND for each participant.

Statistical analysis

We compared the data for each subject between the CD and ND conditions using a Wilcoxon signed-rank test with a statistical significance level of 5%. Statistical analysis software (SPSS Statistics version 21; IBM Japan, Tokyo, Japan) was used to perform the statistical analyses.

Results

Typical examples of the trajectory of movement of each measuring point under the CD and ND conditions in the same individual are shown in Fig. 4. We confirmed that the range of

oropharyngeal movement expanded under the ND condition compared with that in the CD condition. Dysphagia-related conditions (e.g., aspiration, laryngeal penetration, increased pharyngeal residue) were not observed in all participants. In addition, the stage II transport was observed in all participants with or without dentures, which means bolus transportation by mastication were showed in all participants regardless of the presence or absence of dentures.

As shown in Fig. 5, the horizontal and vertical ranges of movement of the mandible and hyoid bone significantly increased anteriorly and superiorly under ND condition. The range of movement of the larynx, PPW, and UES also significantly increased anteriorly under ND condition.

The distance of movement of the mandible, hyoid, and larynx significantly increased under the ND condition ($P < 0.001$, $P = 0.007$, $P = 0.032$, respectively). The duration of movement of the mandible was significantly prolonged under the ND condition ($P < 0.001$), whereas duration of movement of the hyoid, larynx, PPW, and UES showed no significant differences (hyoid $P = 0.100$; larynx $P = 0.100$; PPW $P = 0.613$; UES $P = 0.625$). Table 1 shows the mean range, distance, and duration of movements according to the mean ND/CD ratios. The data of the CD condition for each participant were set at 1.0 as reference, and the ND/CD ratio was calculated to eliminate inter-individual differences.

Discussion

The present study revealed that the hyoid, larynx, PPW, and UES did not change their temporal

relationships in pharyngeal swallowing by denture-wearing, whereas, they rather could reduce their range of movement spatially (Fig. 4). It is important for pharyngeal swallowing that the oral cavity and pharynx move in a coordinated state to generate swallowing pressure for pharyngeal bolus passage.^{17,18} Therefore their movements without dentures might be changed not temporally but spatially. Our results also revealed that the range of movement and duration of mandibular movement could be reduced and shortened by denture-wearing, respectively. It is important for hyoid elevation to initiate pharyngeal swallowing that the mandible is fixed by occlusal contacts of upper and lower dentures.¹⁹ In the present study, the mandible and hyoid would need the contact of alveolar ridges and tongue tip instead of occlusal contacts. These changes by denture-wearing indicated that complete dentures might help pharyngeal swallowing function of edentulous individuals during feeding solid food from the prospective of spatial motion analysis. It has been reported that swallowing reserve decreases with age, showing that the decline of maximum UES opening,²⁰ the prolonged hyoid anterior movement and elevation, and the prolonged laryngeal elevation.^{21,22} Present results thus suggested that wearing dentures might improve swallowing function in older individuals with diminished swallowing reserve. In fact, Yoshida et al.¹¹ reported that wearing dentures shortens the duration of pharyngeal bolus passage and it leads to prevents any increase in the risk of aspiration in older individuals with dysphagia requiring nursing care.

Movements of the hyoid bone and pharynx, which play a central role in pharyngeal swallowing, are precisely programmed in the brain stem as the swallowing reflex. The hyoid bone and larynx

are vertically connected by the thyrohyoid muscle and ligaments and are said to have similar movement trajectories.²³ In the present study, the hyoid bone and larynx indeed showed almost the same trend in changes of their movements when dentures were removed. The influence of denture removal on hyoid and laryngeal movements was shown not as a temporal change, rather as a spatial change by expanding the range of movement in the anterosuperior direction. Previous study by Yoshikawa et al.⁸ that have focused on swallowing liquids without dentures also reported that pharyngeal swallowing was not affected temporally by denture removal. The hyoid and larynx of present study might enlarge their movement spatially to compensate for the negative effects of denture removal and to maintain temporal relationships in pharyngeal swallowing because even a small temporal error in their movements might lead directly to increased risk of pharyngeal dysphagia, such as that caused by aspiration.

The expansion of the hyoid and laryngeal movements by denture removal was due to anatomical changes in the oral cavity and pharynx as well as the functional changes in feeding and swallowing. The upper and lower dental arches and jawbone were thus missing, so it was difficult for the tongue to control the bolus without dentures in the oral cavity,²⁴ suggesting poor bolus formation and transportation during feeding. Yamamoto et al.¹² also reported that the bolus was scattered in the oral cavity and pharynx, and the scattered pieces of the bolus thus reached the hypopharynx before swallowing occurred.

In terms of the PPW, it is possible that the anatomical changes in the oral cavity and pharynx

induced changes in contraction of the PPW. Denture removal caused anterior mandibular displacement when swallowing was initiated. It also caused anterior displacement of the tongue base in the oropharynx, resulting in an increased volume of the oropharynx.¹⁵ The level of swallowing pressure is thought to depend on pharyngeal volume. Therefore, when dentures are removed, it is necessary for the PPW to greatly contract in the anterior direction and to generate the same level of swallowing pressure as was present when the dentures were in place. This might be also a compensatory change to decreased pharyngeal swallowing pressure caused by anatomical changes. In addition, it has been shown that contraction of the PPW and opening of the UES are dependent on the size of the bolus.²⁰ Therefore, because of the increased size of the bolus in the pharynx due to poor bolus formation in the oral cavity, it is necessary for the UES and PPW to work harder to make scattered bolus pass through the pharynx safely.

Ishida et al. reported that movement of the hyoid bone in the horizontal direction is principally related to pharyngeal movement, especially the opening of the UES.²⁵ That report supports our findings of the present study in which horizontal hyoid movement and maximum opening of the UES were increased simultaneously. In the present study, there were no differences in the duration of movement of the UES between denture-wearing conditions (or of the hyoid, larynx, or PPW). It has been reported that the duration of opening of the UES is not influenced by age-related changes.²⁰ Thus, similar to other pharyngeal movements, the range of movement of UES expanded to avoid temporal changes associated with denture removal.

The present study is a before and after study and targeted older individuals who wear their dentures daily, so it is possible that the effects of removing dentures had temporary effects and only to a certain level. Moreover, the quality of dentures may influence on swallowing function as Monaco et al. reported that ill-fitting dentures prolonged total swallowing duration compared with new well-fitted dentures.²⁴ For these reasons, further study is needed concerning older individuals who do not use dentures daily, and who use ill-fitting dentures as well as patients with dentures who have dysphagia. With these limitations, the study indicated that older individuals compensate denture absence by enlarging the range of oropharyngeal movements during pharyngeal swallowing to achieve smooth bolus passage thorough the pharynx. Thus, our results suggest that wearing complete dentures plays a significant role in assisting not only oral masticatory function but also pharyngeal swallowing.

Conclusion

We investigated the influences of wearing and removing complete dentures on pharyngeal swallowing in the feeding sequence of solid food in older edentulous individuals, and the following results were observed: During pharyngeal swallowing without dentures, the hyoid bone, larynx, posterior pharyngeal wall, and upper esophageal sphincter do not change their duration of movements but, rather, expand their range of movement. This might be compensatory spatial change of oropharyngeal movement to avoid temporal changes in pharyngeal swallowing. These

findings provide further insight into the effect of wearing dentures in older edentulous individuals.

Acknowledgement

This study was partially supported by a Grant-in-Aid for Scientific Research (C) Japan Society for the Promotion of Science KAKENHI Grant Number 26462933.

Conflict of interest

The authors declare no conflict of interests.

References

1. Siebens H, Trupe E, Siebens A, Cook F, Anshen S, Hanauer R *et al.* Correlates and consequences of eating dependency in institutionalized elderly. *J Am Geriatr Soc.* 1986; 34: 192–198.
2. Ikebe K, Hazeyama T, Morii K, Matsuda K, Maeda Y, Nokubi T. Impact of masticatory performance on oral health-related quality of life for elderly Japanese. *Int J Prosthodont.* 2007; 20: 478–485.
3. Wirth R, Dziewas R, Beck AM, Clavé P, Hamdy S, Heppner HJ *et al.* Oropharyngeal dysphagia in older persons - from pathophysiology to adequate intervention: a review and summary of an international expert meeting. *Clin Interv Aging.* 2016; 23; 11:189-208.
4. Feldman RS, Kapur KK, Alman JE, Chauncey HH. Aging and mastication: changes in performance and in the swallowing threshold with natural dentition. *J Am Geriatr Soc.* 1980; 28: 97–103.
5. Furuta M, Komiya-Nonaka M, Akifusa S, Shimazaki Y, Adachi M, Kinoshita T *et al.* Interrelationship of oral health status, swallowing function, nutritional status, and cognitive ability with activities of daily living in Japanese elderly people receiving home care services due to physical disabilities. *Community Dent Oral Epidemiol.* 2013; 41: 173–181.
6. Minakuchi S, Takaoka S, Ito J, Shimoyama K, Uematsu H. Factors affecting denture use in some institutionalized elderly people. *Spec Care Dentist.* 2006; 26: 101–105.

7. Palmer JB, Hiiemae KM, Liu J. Tongue-jaw linkages in human feeding: a preliminary videofluorographic study. *Arch Oral Biol.* 1997; 42: 429–441.
8. Yoshikawa M, Yoshida M, Nagasaki T, Tanimoto K, Tsuga K, Akagawa Y. Influence of aging and denture use on liquid swallowing in healthy dentulous and edentulous older people. *J Am Geriatr Soc.* 2006; 54: 444–449.
9. Yoshikawa M, Yoshida M, Nagasaki T, Tanimoto K, Tsuga K, Akagawa Y. Effects of tooth loss and denture wear on tongue-tip motion in elderly dentulous and edentulous people. *J Oral Rehabil.* 2008; 35 882–888.
10. Kondoh J, Ono T, Tamine K, Fujiwara S, Minagi Y, Hori K *et al.* Effect of complete denture wearing on tongue motor biomechanics during swallowing in edentulous older adults. *Geriatr Gerontol Int.* 2015; 15: 565-571.
11. Yoshida M, Masuda S, Amano J, Akagawa Y. Immediate effect of denture wearing on swallowing in rehabilitation hospital inpatients. *J Am Geriatr Soc.* 2013; 61: 655–657.
12. Gokce HS, Gokce SM, Akin E, Bulakbasi N, Akyol M. Effect of complete denture wearing on deglutition time: a cine-magnetic resonance imaging study. *J Oral Rehabil.* 2012; 39: 198-209.
13. Yamamoto H, Furuya J, Tamada Y, Kondo H. Impacts of wearing complete dentures on bolus transport during feeding in elderly edentulous. *J Oral Rehabil.* 2013; 40: 923–931.
14. Hiiemae KM, Palmer JB. Food transport and bolus formation during complete feeding sequences on foods of different initial consistency. *Dysphagia.* 1999; 14: 31-42.

15. Furuya J, Tamada Y, Sato T, Hara A, Nomura T, Kobayashi T *et al.* Wearing complete dentures is associated with changes in the three-dimensional shape of the oropharynx in edentulous older people that affect swallowing. *Gerodontology*. 2015. doi: 10.1111/ger.12197.
16. Hiimae KM, Palmer JB. Food transport and bolus formation during complete feeding sequences on foods of different initial consistency. *Dysphagia*. 1999; 14: 31–42.
17. Li Q, Minagi Y, Hori K, Kondoh J, Fujiwara S, Tamine K *et al.* Coordination in oro-pharyngeal biomechanics during human swallowing. *Physiol. Behav.* 2015; 1; 147: 300-305.
18. Kahrilas PJ, Logemann JA, Lin S, Ergun GA. Pharyngeal clearance during swallowing: a combined manometric and videofluoroscopic study. *Gastroenterology*. 1992; 103: 128–136.
19. Tamura F, Mizukami M, Ayano R, Mukai Y. Analysis of feeding function and jaw stability in bedridden elderly. *Dysphagia*. 2002; 17: 235–241.
20. Shaw DW, Cook IJ, Gabb M, Holloway RH, Simula ME, Panagopoulos V *et al.* Influence of normal aging on oral-pharyngeal and upper esophageal sphincter function during swallowing. *Am J Physiol*. 1995; 268(3 Pt 1): G389–G396.
21. Logemann JA, Pauloski BR, Rademaker AW, Colangelo LA, Kahrilas PJ, Smith CH. Temporal and biomechanical characteristics of oropharyngeal swallow in younger and older men. *J Speech Lang Hear Res*. 2000; 43: 1264–1274.
22. Logemann JA, Pauloski BR, Rademaker AW, Kahrilas PJ. Oropharyngeal swallow in younger and older women: videofluoroscopic analysis. *J Speech Lang Hear Res*. 2002; 45: 434–445.

23. Steele CM, Bailey GL, Chau T, Molfenter SM, Oshalla M, Waito AA *et al.* The relationship between hyoid and laryngeal displacement and swallowing impairment. *Clin Otolaryngol.* 2011; 36: 30–36.
24. Imaizaki T, Nishi Y, Kaji A, Nagaoka E. Role of the artificial tooth arch during swallowing in edentates. *J Prosthodont Res.* 2010; 54: 14–23.
25. Ishida R, Palmer JB, Hiemae KM. Hyoid motion during swallowing: factors affecting forward and upward displacement. *Dysphagia.* 2002; 17: 262–272.
26. Monaco A, Cattaneo R, Masci C, Spadaro A, Marzo G. Effect of ill-fitting dentures on the swallowing duration in patients using polygraphy. *Gerodontology.* 2012; 29: e637–e644.

Table 1 Changes in movement parameters: wearing no dentures versus wearing complete dentures.

			Ratio of ND to CD AVE (SD)	<i>P</i> -value
Range of movement				
Mandible	Horizontal		2.97 (1.77)***	<0.001
	Vertical		4.17 (2.34)***	<0.001
Hyoid	Horizontal		1.18 (0.28)*	0.010
	Vertical		1.18 (0.37)*	0.029
Larynx	Horizontal		1.33 (0.43)**	0.002
	Vertical		1.06 (0.21)	0.098
PPW contraction			1.22 (0.24)**	0.001
UES opening			1.09 (0.14)*	0.012
Distance of movement				
Mandible			2.85 (2.09)***	<0.001
Hyoid			1.16 (0.25)**	0.007
Larynx			1.10 (0.20)*	0.032
Duration of movement				
Mandible			4.20 (2.46)***	<0.001
Hyoid			1.03 (0.09)	0.100
Larynx			1.03 (0.09)	0.100
PPW contraction			1.01 (0.05)	0.613
UES opening			1.00 (0.05)	0.625

* $P < 0.05$; ** $P < 0.01$; *** $P < 0.001$. The data for each participant when wearing dentures was set at 1 as the reference. We subsequently calculated the ND/CD ratio and the mean rates of change in each subject after the dentures were removed. ND/CD ratios are given as the average (SD). ND, wearing no dentures; CD, wearing complete dentures; PPW, posterior pharyngeal wall; UES, upper esophageal sphincter; SD, standard deviation.

Figure legends

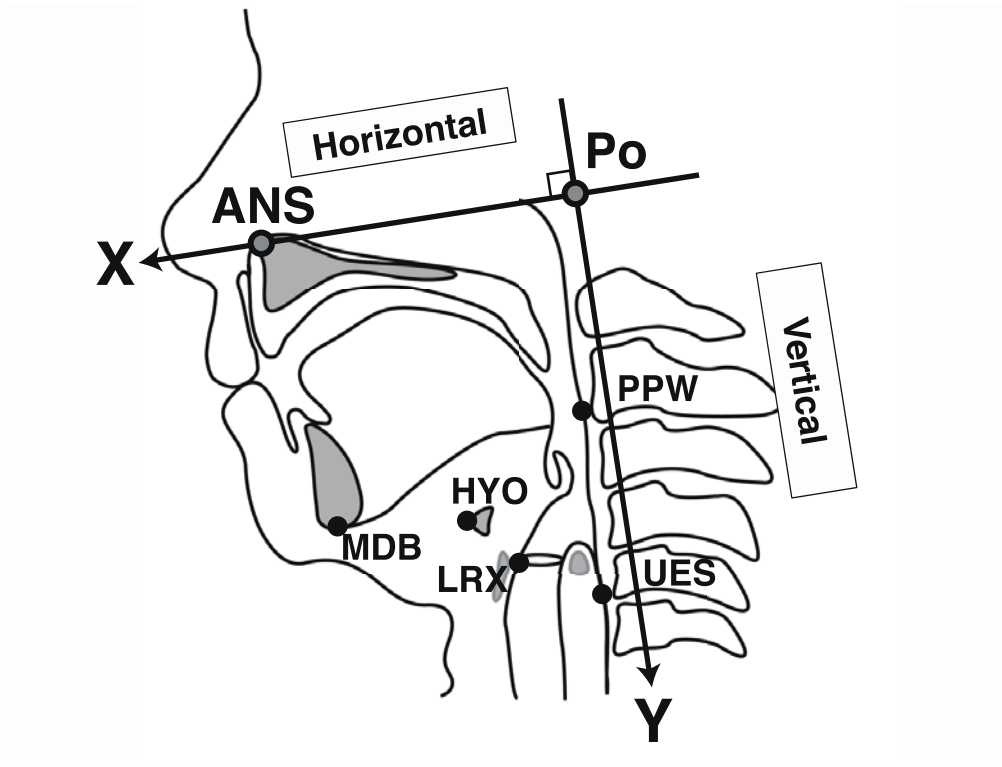


Fig. 1. Oropharyngeal measurement points during a videofluoroscopic study of swallowing. MDB, mandible, lowermost point of the mental protuberance; HYO, hyoid bone, anterior uppermost point of hyoid bone; LRX, larynx, anterior uppermost point of subglottic air column; PPW, posterior pharyngeal wall, level of the lower margin of the second cervical vertebra; UES, upper esophageal sphincter, level of the lower margin of the fifth cervical vertebra; Po, origin, midpoint of the lead ball placed on the superior border of the tragus used for reference; ANS, tip of the anterior nasal spine. X, x-axis, horizontal line passing through ANS and Po, which shows the anteroposterior positions in the horizontal reference plane; Y, y-axis, vertical line perpendicular to the x-axis that meets at Po, which shows the vertical positions to the horizontal plane.

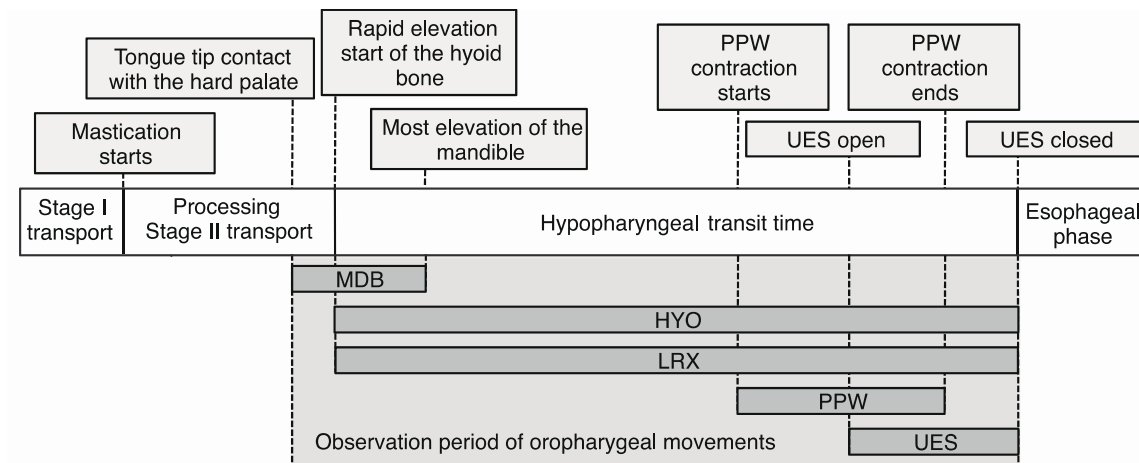


Fig. 2. Observation of oropharyngeal measurement point. MDB, duration of mandibular movement during swallowing, from the contact of the tip of the tongue with the hard palate for bolus transport to the maximum elevation of the chin during the swallowing reflex; HYO and LRX, duration of hyoid bone and laryngeal movements, from the start of the superior movement of the hyoid bone to UES closure; PPW, duration of posterior pharyngeal wall contraction, from the start of the contraction until return to the original relaxed position; UES, duration of upper esophageal sphincter opening, from the start of the opening to closure.



Fig. 3. Methods for measuring the range of movements. The trajectory of all movements of each measurement point during observation were drawn by spreadsheet software (Microsoft Excel 2010; Microsoft Corporation, Redmond, WA, USA), which were output as still images along with the x- and y-axes for calibration. The horizontal range of the x-axis and vertical range of the y-axis were then measured using the distance measurement tool of image editing software (Adobe Photoshop CS5.1; Adobe Systems Inc.). PPW, posterior pharyngeal wall; UES, upper esophageal sphincter.

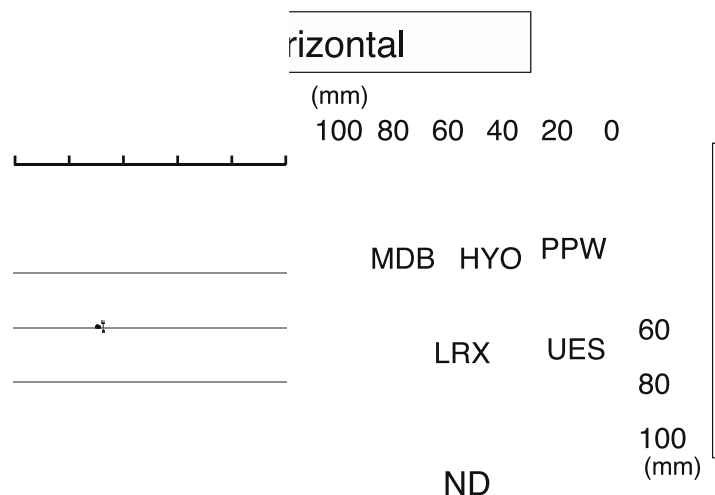


Fig. 4. Typical examples of the trajectory of oropharyngeal movements under conditions of wearing complete dentures (CD) and not wearing dentures (ND). The total distance increased for the mandible, hyoid, and larynx more under the ND condition than under the CD condition, with the range of movement expanding in the anterosuperior direction. PPW and UES expanded horizontally under the ND condition. CD, wearing complete dentures; ND, wearing no dentures; MDB, mandible; HYO, hyoid bone; LRX, larynx; PPW, posterior pharyngeal wall; UES, upper esophageal sphincter.

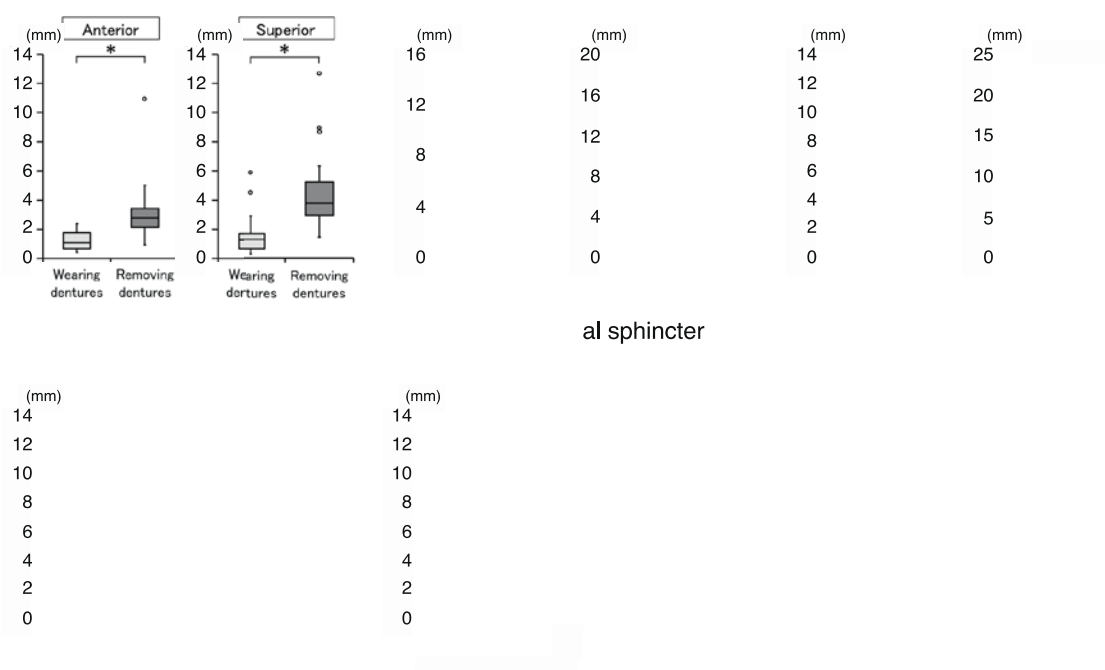


Fig. 5. Range of movements of oropharyngeal organs during pharyngeal swallowing. (a) The range of motion of the mandible significantly increased in the horizontal and vertical directions under the ND condition, with expansion in the anterosuperior direction (horizontal direction: $P < 0.001$, vertical direction: $P < 0.001$). (b) The range of motion of the hyoid significantly increased in the horizontal and vertical directions under the ND condition, with expansion in the anterosuperior direction (horizontal direction: $P = 0.01$, vertical direction: $P = 0.029$). (c) The range of motion of the larynx significantly increased in the horizontal direction under the ND condition, with expansion in the anterior direction. In contrast, although there was a trend to expand in the superior direction in the vertical range of motion of the larynx, no significant differences were noted (horizontal direction: $P = 0.002$, vertical direction: $P = 0.098$). (d), (e) The range of PPW contraction and UES opening were significantly increased under the ND condition (PPW: $P = 0.001$, UES: $P = 0.012$).

CD, wearing complete dentures; ND, wearing no dentures; PPW, posterior pharyngeal wall; UES, upper esophageal sphincter.