

研 究

Increase in ^{18}F -FDG accumulation in gingival cancer with bone resorption compared with ^{18}F -choline

Keisuke Saito, Mitsuru Izumisawa, Yasufumi Hara*, Kazunori Terasaki**, Ren Iwata***,
Yoshihiko Sugiyama*

Division of Dental Radiology, Department of Reconstructive Oral and Maxillofacial Surgery, School of Dentistry,
Iwate Medical University (Chief : Prof. Masanori Shozushima)

*Division of Oral and Maxillofacial Surgery, Department of Reconstructive Oral and Maxillofacial Surgery,
School of Dentistry, Iwate Medical University (Chief : Prof. Yoshihiko Sugiyama)

**Cyclotron Research Center, Iwate Medical University

***Cyclotron and Radioisotope Center, Tohoku University

[Received : October 27, 2016 : Accepted : November 11, 2016]

Abstract : We often observed that ^{18}F -FDG accumulation in gingival cancer with bone resorption was higher than that in tongue cancer. In this study, we statistically compared accumulation of ^{18}F -FDG in gingival cancer with bone resorption with accumulation in tongue cancer. We also compared it with ^{18}F -labeled choline (^{18}F -choline) PET to clarify the characteristics of ^{18}F -FDG accumulation in bone resorption.

The subjects were 57 patients with gingival cancer and 34 patients with tongue cancer. Histologically, all cases were squamous cell carcinoma. ^{18}F -FDG and ^{18}F -choline accumulations were evaluated using the maximum standardized uptake value (SUV) .

Comparison of ^{18}F -FDG SUV between tongue cancer and gingival cancer without bone resorption showed no significant difference; however, the comparison between tongue cancer and gingival cancer with bone resorption resulted in values of 6.6 and 10.4, respectively, showing a significantly higher ^{18}F -FDG SUV in gingival cancer accompanied by bone resorption ($p = 0.001$) . The SUV of ^{18}F -choline in tongue cancer was similar to that of ^{18}F -FDG, but unlike with ^{18}F -FDG, the SUV was not significantly higher in gingival cancer with bone resorption.

The mean ^{18}F -FDG PET SUV was higher in gingival cancer with bone resorption than in tongue cancer, although this finding was not observed with ^{18}F -choline. It was assumed that the high ^{18}F -FDG SUV was due to accumulation in osteoblasts and osteoclasts involved in bone metabolism in addition to cancer stromal cells.

Key words : PET, ^{18}F -FDG, ^{18}F -choline, bone resorption, gingival cancer

Introduction

Positron emission tomography (PET) has an important role as a new imaging diagnosis

method for malignant tumors in the head and neck region¹⁾. A glucose analog, ^{18}F -fluorodeoxyglucose (^{18}F -FDG) , is the most widely used radiopharmaceutical for PET

within this region, although ^{11}C -labeled choline (^{11}C -choline) or ^{18}F -labeled choline (^{18}F -choline) PET is also used as a diagnostic tool in clinical oncology²⁾. The uptake level of ^{18}F -FDG is considered an important factor, and it used not only to judge the effect of radiotherapy, but also to predict the outcome³⁾. Generally, the accumulation level is numerically presented as a standardized uptake value (SUV). Kitagawa et al.⁴⁾ reported that, after administering combined intra-arterial chemotherapy and radiotherapy to 15 head and neck cancer patients, residual tumor was present in three of the eight patients with a pretreatment SUV higher than 7, whereas the post-treatment biopsy was negative in all patients with a pretreatment SUV lower than 7. Halfpenny et al.⁵⁾ reported that the survival rate of head and neck cancer patients markedly decreased when the SUV of the primary lesion was higher than 10, thus demonstrating the importance of SUV. However, SUV changes depending on the state of tumor cells. For example, Minn et al.⁶⁾ reported that the SUV rose with an increase in the cell proliferation index, and Izumisawa et al.⁷⁾ reported that the SUV rose with an increase in the tumor cell density of squamous cell carcinoma of the head and neck region. Although the SUV may

be influenced by several factors, as described above, the influences of the cancer development site and invaded region have not been sufficiently clarified. We often observe that ^{18}F -FDG accumulation in gingival cancer is higher than in other oral cavity cancers, which most frequently develop from head and neck cancers. This study focuses on tongue and gingival cancers because of the large numbers of patients with oral cavity cancer. We investigated changes in ^{18}F -FDG accumulation due to the presence or absence of cancer resorption of bone in the mandible and maxilla, and examined whether another PET tumor tracer, ^{18}F -choline, shows a similar accumulation characteristic. This study aimed to clarify the characteristics of ^{18}F -FDG uptake in oral cavity cancers.

Materials and Methods

All study protocols were approved by the ethics committee at Iwate Medical University, School of Dentistry (no. 01083). The subjects were 34 patients with tongue cancer (mean age: 62.2 years old) and 57 patients with gingival cancer (21 maxilla and 36 mandible, mean age: 68.0 years old) who visited our institution between November 1995 and December 2011 (Fig.1). ^{18}F -FDG PET was

Division of Dental Radiology, Department of Reconstructive Oral and Maxillofacial Surgery, School of Dentistry, Iwate Medical University (Chief : Prof. Masanori Shozushima)

*Division of Oral and Maxillofacial Surgery, Department of Reconstructive Oral and Maxillofacial Surgery, School of Dentistry, Iwate Medical University (Chief : Prof. Yoshiki Sugiyama)

**Cyclotron Research Center, Iwate Medical University

***Cyclotron and Radioisotope Center, Tohoku University

1-3-27 Chouo-dori, Morioka, Iwate 020-8505, Japan

*1-3-27 Chouo-dori, Morioka, Iwate 020-8505, Japan

**348-58 Tomegamori, Takizawa, Iwate 020-0603, Japan

***6-3 Aoba, Aramaki, Aobaku, Sendai, Miyagi 980-8578, Japan

岩手県盛岡市中央通1丁目3-27 (〒020-8505)

*岩手県盛岡市中央通1丁目3-27 (〒020-8505)

**岩手県滝沢市留が森348-58 (〒020-0603)

***宮城県仙台市青葉区荒巻字青葉6-3 (〒980-8578)

Dent. J. Iwate Med. Univ. 41 : 29-38, 2017

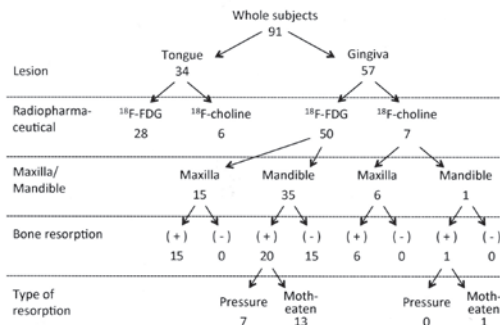


Fig. 1 : Number of subjects by classification criteria in this study

performed in 28 tongue cancer patients and 50 gingival cancer patients (15 maxilla and 35 mandible), while ^{18}F -choline PET was performed in six tongue cancer patients and seven gingival cancer patients (six maxilla and one mandible). All patients were histopathologically diagnosed with squamous cell carcinoma. In the gingival cancer patients, the presence or absence of bone resorption was examined using panoramic and CT images. Bone resorption was present in all of 15 gingival cancer patients in the maxilla examined with ^{18}F -FDG PET. When bone resorption was present in the mandible, the resorption type was classified into pressure or moth-eaten types. The pressure type was defined as clear and smooth bone resorption, with relatively homogeneous radiolucency of the lesion, and the moth-eaten type was defined as bone resorption, with an irregular unclear boundary, and diffuse and heterogeneous radiolucency of the lesion. The bone resorption type was judged by three dental radiologists with 5 years or more of experience in imaging diagnosis. Bone resorption in the mandible was present in 20 out of 35 patients examined by ^{18}F -FDG: 7 and 13 cases of the pressure and moth-eaten types,

respectively. Bone resorption in the mandible and maxilla was present in all of the seven gingival cancer patients examined with ^{18}F -choline PET. Bone resorption type of one mandible cancer patient examined with ^{18}F -choline was moth-eaten type.

PET scanning protocol

^{18}F -FDG and ^{18}F -choline were synthesized at Iwate Medical University Cyclotron Research Center. ^{18}F -fluoromethyl choline (^{18}F -choline) was synthesized from [^{18}F] fluoromethyl triflate ([^{18}F] CH_2FOTf) according to the method reported by Iwata et al.⁸⁾ ^{18}F -FDG or ^{18}F -choline was intravenously administered to patients after they had fasted for 6 hours or longer. The blood glucose level at the time of PET was lower than 150 mg/dl in all patients. The PET devices used were a Head Tome IV (Shimadzu, Kyoto, Japan), or a SET 3000GCT/M (Shimadzu, Kyoto, Japan), both with a full width at half maximum of 6 mm. PET images were acquired under the following conditions: field of view, 256 mm \times 256 mm; matrix, 128 \times 128; pixel size, 2.0 \times 2.0 mm; and slice thickness, 2.6 mm. Transmission scans were obtained for 10 min using a standard ring source of $^{68}\text{Ge}/^{68}\text{Ga}$ for attenuation correction of the emission images. Subsequently, a dose of 3.7 MBq/kg of ^{18}F -FDG was injected intravenously 60 min before the start of the whole-body PET/CT scan. For the ^{18}F -choline imaging, a dose of 3.7 MBq/kg of ^{18}F -choline was injected intravenously 5 min before the start of the PET/CT. PET and CT data were analyzed using the medical imaging analysis application Dr. View (AJS, Tokyo, Japan). For the quantitative evaluation of regional radioactivity from the static PET images, regions of interest (circular, 10 mm in diameter) were examined in the area of

highest accumulated radioactivity. These tissue radioactivities were corrected with the injected doses and patients' body weights, to calculate the SUV using the following formula:

$$\text{SUV} = \frac{\text{radioactivity concentration in the ROI [Bq/ml]} / (\text{injected dose of } ^{18}\text{F-FDG or } ^{18}\text{F-choline) [Bq]} / \text{patient body weight [g]}}{1}$$

Statistical analysis

SUV values were compared by classifications shown in Fig. 1. Before comparison tests, normality of distribution of each group was examined by Kolmogorov-Smirnov test. In case of normal distribution, t-test was performed to compare the difference of mean SUV between groups. While, in not normal distribution, Mann-Whitney's U test was used for comparison between 2 groups, and Kruskal-wallis test following multiple comparisons with Bonferroni's correction was used for comparisons for 3 groups. All statistical analyses were conducted using SPSS version 23 for Windows (IBM) .

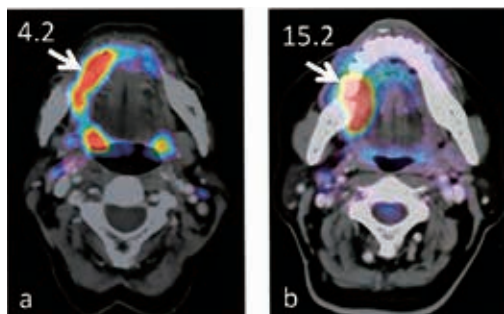


Fig.2 : ^{18}F -FDG PET/CT in tongue and gingival cancers

The histologic type was squamous cell carcinoma in both cases, but ^{18}F -FDG accumulation was higher in gingival cancer with bone resorption.

a, right tongue cancer, SUVmax = 4.2.

b, right lower gingival cancer accompanied by bone resorption (arrow) , SUV = 15.2.

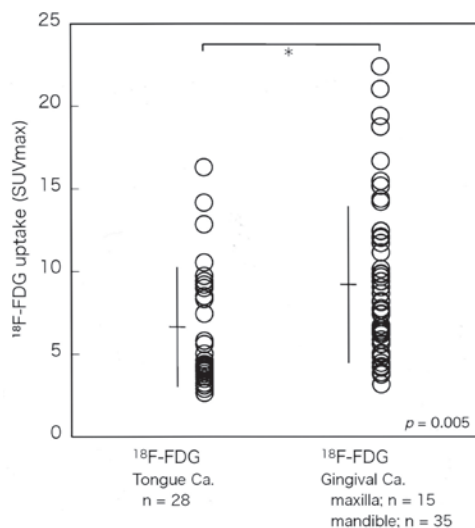


Fig.3 : ^{18}F -FDG SUV in tongue cancer and gingival cancer

The mean SUV in tongue cancer (n = 28) and gingival cancer (n = 50) was 6.6 and 9.2, respectively, showing that ^{18}F -FDG more markedly accumulated in gingival cancer than in tongue cancer (p = 0.005) .

Results

1. ^{18}F -FDG accumulation in tongue and gingival cancers

^{18}F -FDG PET/CT images of tongue cancer and gingival cancer are shown in Fig. 2. This is an initially examined a patient. When an ROI was set in the region with high ^{18}F -FDG accumulation within the primary lesion, the SUV values were 4.2 and 15.2, respectively, showing higher SUV in gingival cancer than in tongue cancer. Therefore, the SUV was compared between the 28 tongue cancer and 50 gingival cancer patients examined with ^{18}F -FDG PET (Fig. 3) . The mean SUV was 6.6 and 9.2, respectively. Mann-Whitney test revealed that there was significant difference in SUV between patients with tongue and gingiva cancers (p = 0.005) . The gingival cancer patients were further divided into those

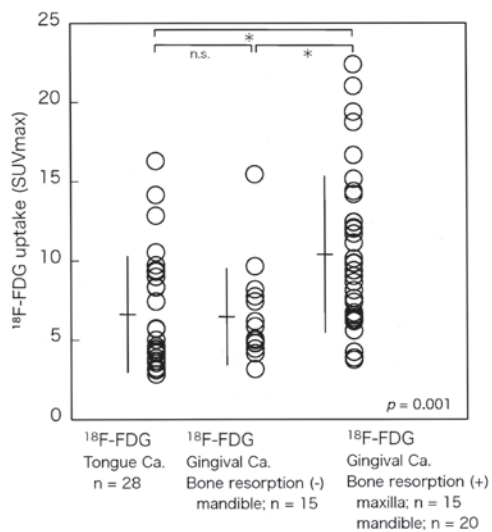


Fig.4 : ^{18}F -FDG SUV in tongue cancer and gingival cancer with and without bone resorption
No significant difference was noted in the mean SUV between gingival cancer without bone resorption ($n = 15$) and tongue cancer ($n = 28$; SUV: 6.5 vs. 6.6) ; however, the mean SUV was 10.4 in gingival cancer with bone resorption ($n = 35$), which was a significantly higher accumulation than in tongue cancer ($p = 0.001$).

with ($n = 35$) and without ($n = 15$) bone resorption, and the ^{18}F -FDG SUV was compared with that in the tongue cancer patients ($n = 28$; Fig. 4). A comparison between tongue cancer and gingival cancer without bone resorption revealed mean SUV values of 6.6 and 6.5, respectively, whereas the mean SUV in gingival cancer with bone resorption was 10.4. Kruskal-Wallis test showed difference among the 3 groups. By post-hoc multiple comparison tests, statistically significant differences were found between tongue and bone resorption ($p = 0.001$), and between without bone resorption and bone resorption. These findings clarified the observations that ^{18}F -FDG accumulation changed markedly depending on the presence or absence of bone resorption.

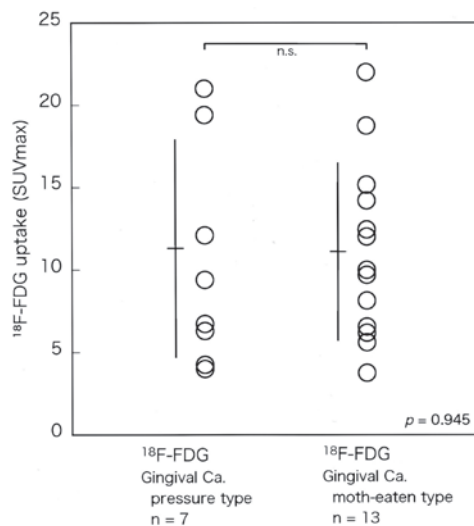


Fig.5 : ^{18}F -FDG SUV in gingival cancer by bone resorption type in mandible
The mean SUV was 11.3 and 11.2 in the pressure ($n = 7$) and moth-eaten ($n = 13$) types, respectively, showing no significant difference between the bone resorption types ($p = 0.945$).

On the basis of the bone resorption type, the lower gingival cancer patients were classified into the pressure ($n = 7$) and moth-eaten ($n = 13$) types, according to the criteria described in the Methods section. Since distribution of SUV in both groups had normality, t test was performed to compare the averages. The mean ^{18}F -FDG SUV was 11.3 and 11.2 for the pressure and moth-eaten types, respectively (Fig. 5), showing no significant difference ($p = 0.945$). There was therefore no indication that ^{18}F -FDG accumulation depended on the bone resorption type.

2. ^{18}F -FDG and ^{18}F -choline accumulations

As shown in Fig. 4, the ^{18}F -FDG SUV was high in gingival cancer with bone resorption. For comparison purposes, PET was also performed using ^{18}F -choline. Firstly, to confirm that the ^{18}F -choline SUV in malignant tumors is equivalent to the ^{18}F -FDG SUV, the SUV

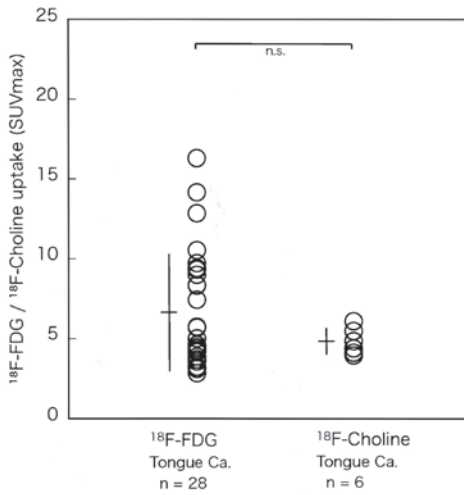


Fig.6 : ^{18}F -FDG and ^{18}F -choline SUV in tongue cancer

The mean ^{18}F -FDG (n = 28) and ^{18}F -choline SUV (n = 6) in tongue cancer was 6.6 and 4.8, respectively, showing no significant difference.

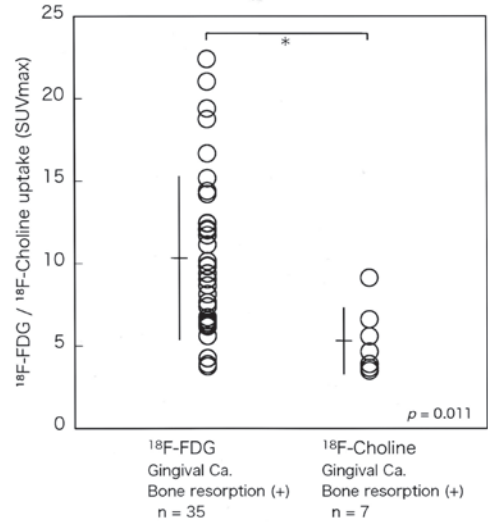


Fig.7 : ^{18}F -FDG and ^{18}F -choline SUV in gingival cancer accompanied by bone resorption

The mean ^{18}F -FDG (n = 35) and ^{18}F -choline SUV (n = 7) was 10.4 and 5.3, respectively, showing higher accumulation of ^{18}F -FDG than ^{18}F -choline (p = 0.011) .

from the two tracers was compared within the tongue cancer patients. As shown in Fig. 6, the mean ^{18}F -FDG and ^{18}F -choline SUV in the tongue cancer patients (n = 6) was 6.6 and 4.8, respectively. The mean ^{18}F -choline SUV was slightly lower, but there was no difference in rank of SUV between ^{18}F -FDG and ^{18}F -choline groups by Mann-Whitney's U test. The SUV of the two tracers was then compared in the patients with gingival cancer accompanied by bone resorption. Since distributions of SUV in both groups were normal, t test was performed to compare between groups. As shown in Fig. 7, the mean ^{18}F -FDG (n = 35) and ^{18}F -choline (n = 7) SUV was 10.4 and 5.3, respectively, showing that ^{18}F -choline did not result in an increased SUV (p = 0.011) .

Discussion

Head and neck cancers most frequently develop in the oral cavity, and squamous cell

carcinomas account for more than 90% of cases^{9) . 10)} . Gingival cancer has the second highest incidence rate among head and neck cancers (tongue cancer has the highest) , and the frequency of mandibular resorption in gingival cancer is high (12–56%)¹¹⁻¹³⁾ . CT and MRI have routinely been used for imaging diagnosis of oral cavity cancers, with ^{18}F -FDG PET recently becoming established as an index of the biological malignancy of cancer. Glucose metabolism is promoted in malignant tumor cells, and the glucose analog ^{18}F -FDG, is incorporated into tumor cells^{14) . 15)} ; therefore, ^{18}F -FDG PET allows visualization of this promoted tumor cell glucose metabolism. By contrast, choline is incorporated into two classes of phospholipids that are constituents of cell membranes. In general, the choline-containing compound level of tumor cells is enhanced because of the high proliferation rate, although the presence of a complex

interaction between oncogenic signaling and choline metabolic pathways was recently reported^{16) . 17)}. Choline-based PET tracers are used to diagnose malignant tumors in various parts of the body, including prostate cancer, brain tumors, and head and neck cancers¹⁸⁾. ^{18}F -choline analogs include ^{18}F -fluoroethyl-choline and ^{18}F -fluoromethyl-choline, and DeGrado et al.¹⁹⁾ demonstrated the superiority of the latter for use as an oncologic tracer. In our study, we used ^{18}F -fluoromethyl-choline, which was chemically synthesized according to the method of Iwata et al.⁸⁾ and it may be that this was favorably accumulated in the primary lesions.

We adopted the maximum SUV (SUVmax) as a parameter to represent ^{18}F -FDG accumulation in PET; however, some studies report that SUVmax does not accurately reflect the overall metabolism of a tumor as it is based on the evaluation of one voxel²⁰⁾. Metabolic tumor volume (MTV) and total lesion glycolysis (TLG) are increasingly being reported as being useful for representing volume-based tumor ^{18}F -FDG accumulation²¹⁾. However, MTV and TLG have not yet been widely employed in general medical practice, as they require specialized analysis. Thus, we employed SUVmax, which is a simple and frequently used index.

Many studies used ^{18}F -FDG SUV to evaluate the malignancy and proliferation rate of head and neck cancers, and enhanced glucose metabolism correlates with patient outcome, regardless of the selected treatment method reported^{3) . 5) . 22)}. SUV is also an independent prognostic factor for the survival rate of recurrent cases^{23) . 24)}. Therefore, both the accumulation site and the SUV of ^{18}F -FDG are important information for the diagnosis of malignant tumors. The SUV depends on the

mitotic index of a tumor and tumor cell density^{6) . 7)}. However, as shown in Figs. 3 and 4, ^{18}F -FDG accumulates more markedly in gingival cancer than in tongue cancer. In addition, no difference was noted between tongue cancer and gingival cancer in the absence of bone resorption, but in the presence of bone resorption ^{18}F -FDG accumulation was about twice as high. The submucosal fat layer is absent in gingiva, the origin of gingival cancer, and bone tissue is present directly below the mucosa. Accordingly, when cancer advances, the tumor infiltrates into the alveolar bone and the body of the bone, and frequently shows an osteolytic property. It was reported that, in bone metastases of breast cancer, the ^{18}F -FDG SUV was higher in osteolytic than in osteoblastic bone metastases^{25) . 26)}, which supports our finding of increased SUV in osteolytic resorption. As shown in Fig. 5, the ^{18}F -FDG SUV did not depend on the bone resorption type, that is, the pressure and moth-eaten types. This may have been due to the absence of differences in the density or activation of bone metabolism-related cells.

In our study, an accumulation of ^{18}F -choline in tongue cancer was noted, similar to the observed ^{18}F -FDG PET accumulation (Fig. 6), and, although the mean SUV was slightly lower for ^{18}F -choline PET, the difference was not significant. The slightly lower ^{18}F -choline SUV in tongue cancer in comparison with the ^{18}F -FDG SUV may have been due to ^{18}F -choline not being incorporated into inflammatory cells, and may not actually be due to lower uptake by tumor cells²⁷⁾. Kubota et al.²⁸⁾ reported that, when ^{18}F -FDG was administered to a mouse tumor model prepared by transplanting FM3A tumors into mice, 77% of the accumulation was in tumor cells, but 23% was in cancer stromal cells

surrounding tumor cells, such as macrophages and granulation tissue. Additionally, ^{18}F -choline did not result in increased SUV in cases with bone resorption, unlike ^{18}F -FDG (Fig. 7).

Histological analysis of gingival squamous cell carcinoma demonstrated that tumor stroma is composed of various cells, such as fibroblasts, myofibroblasts, endothelial cells, and inflammatory cells²⁹⁾. Kayamori et al.³⁰⁾ reported that parathyroid hormone-related peptide produced by oral squamous cell carcinoma cells, and stromal cell-mediated interleukin-6, bind to receptors on fibroblastic cells and osteoblasts and promote NF- κ B ligand (RANKL) production. RANKL then activates osteoclast formation and bone resorption through osteoclast precursor cells. On this basis, it is assumed that the high SUV in cases with bone resorption is closely related to ^{18}F -FDG accumulation in not only tumor cells and tumor stromal cells, but also bone metabolism-related cells represented by osteoclasts, osteoblasts, and osteoclast precursor cells. As low sensitivity to ^{18}F -FDG has been reported for osteoblastic lesions^{31) 32)}, it may be more likely to accumulate in osteoclasts and osteoclast precursor cells than in osteoblasts. However, a detailed study is necessary to verify this hypothesis. Generally, oral cavity cancers accompanied by bone resorption are progressive and which have a bad prognosis^{33) 34)}. This study confirmed high ^{18}F -FDG SUV in gingival cancer with bone resorption. The SUV serves as an important prognostic factor, and it may appear high because of bone resorption by the cancer, which then requires imaging diagnosis using CT and MRI.

Acknowledgments

The authors gratefully acknowledge the

valuable support of Professor Masanori Shozushima. We are greatly indebted to the staff of the Nishina Memorial Cyclotron Center (NMCC). This study was supported by MEXT KAKENHI Grant Number 24592840.

COI Disclosure

I have no financial relationships to disclose.

References

- 1) Lonneux, M., Hamoir, M., Reyckler, H., Maingon, P., Duvillard, C., Calais, G., Bridji, B., Digue, L., Toubeau, M., Gregoire, V. :Positron emission tomography with [^{18}F] fluorodeoxyglucose improves staging and patient management in patients with head and neck squamous cell carcinoma: a multicenter prospective study. *J. Clin. Oncol.*, 28:1190-1195, 2010.
- 2) Wedman, J., Pruijm, J., Roodenburg, J. L., Halmos, G. B., Langedijk, J. A., Dierckx, R. A., van der Laan, B. F. :Alternative PET tracers in head and neck cancer. A review. *Eur. Arch. Otorhinolaryngol.*, 270:2595-2601, 2013.
- 3) Allal, A. S., Dulguerov, P., Allaoua, M., Haeggeli, C. A., El-Ghazi el, A., Lehmann, W., Slosman, D. O. :Standardized uptake value of 2- [^{18}F] fluoro-2-deoxy-D-glucose in predicting outcome in head and neck carcinomas treated by radiotherapy with or without chemotherapy. *J. Clin. Oncol.*, 20:1398-1404, 2002.
- 4) Kitagawa, Y., Sadato, N., Azuma, H., Ogasawara, T., Yoshida, M., Ishii, Y., Yonekura, Y. :FDG PET to evaluate combined intra-arterial chemotherapy and radiotherapy of head and neck neoplasms. *J. Nucl. Med.*, 40:1132-1137, 1999.
- 5) Halfpenny, W., Hain, S. F., Biassoni, L., Maisey, M. N., Sherman, J. A., McGurk, M. :FDG-PET. A possible prognostic factor in head and neck cancer. *Br. J. Cancer*, 86:512-516, 2002.
- 6) Minn, H., Joensuu, H., Ahonen, A., Klemi, P. :Fluorodeoxyglucose imaging: a method to assess the proliferative activity of human cancer in vivo. Comparison with DNA flow cytometry in head and neck tumors. *Cancer*, 61:1776-1781, 1988.
- 7) Izumisawa, M., Shozushima, M., Sato, H. :The relationship between histopathological findings in oral squamous cell carcinoma and FDG uptake on PET. *Oral Radiology*, 19:149-157, 2003.
- 8) Iwata, R., Pascali, C., Bogni, A., Furumoto, S., Terasaki, K., Yanai, K. : [^{18}F] fluoromethyl triflate, a novel and reactive [^{18}F] fluoromethylating agent: preparation and application to the

- on-column preparation of [18F] fluorocholeline. *Appl. Radiat. Isot.*, 57:347-352, 2002.
- 9) Choi, S., Myers, J. N. :Molecular pathogenesis of oral squamous cell carcinoma: implications for therapy. *J. Dent. Res.*, 87:14-32, 2008.
 - 10) Cooper, J. S., Porter, K., Mallin, K., Hoffman, H. T., Weber, R. S., Ang, K. K., Gay, E. G., Langer, C. J. :National Cancer Database report on cancer of the head and neck: 10-year update. *Head Neck*, 31:748-758, 2009.
 - 11) Chen, Y. L., Kuo, S. W., Fang, K. H., Hao, S. P. :Prognostic impact of marginal mandibulectomy in the presence of superficial bone invasion and the nononcologic outcome. *Head Neck*, 33:708-713, 2011.
 - 12) Hoffmannova, J., Foltan, R., Vlk, M., Sipos, M., Horka, E., Pavlikova, G., Kufa, R., Bulik, O., Sedy, J. :Hemimandibulectomy and therapeutic neck dissection with radiotherapy in the treatment of oral squamous cell carcinoma involving mandible: a critical review of treatment protocol in the years 1994-2004. *Int. J. Oral Maxillofac. Surg.*, 39:561-567, 2010.
 - 13) Lubek, J., El-Hakim, M., Salama, A. R., Liu, X., Ord, R. A. :Gingival carcinoma: retrospective analysis of 72 patients and indications for elective neck dissection. *Br. J. Oral Maxillofac. Surg.*, 49:182-185, 2011.
 - 14) Gallagher, B. M., Fowler, J. S., Guttererson, N. I., MacGregor, R. R., Wan, C. N., Wolf, A. P. :Metabolic trapping as a principle of radiopharmaceutical design: some factors responsible for the bio-distribution of [18F] 2-deoxy-2-fluoro-D-glucose. *J. Nucl. Med.*, 19:1154-1161, 1978.
 - 15) Som, P., Atkins, H. L., Bandyopadhyay, D., Fowler, J. S., MacGregor, R. R., Matsui, K., Oster, Z. H., Sacker, D. F., Shiue, C. Y., Turner, H., Wan, C. N., Wolf, A. P., Zabinski, S. V. :A fluorinated glucose analog, 2-fluoro-2-deoxy-D-glucose (F-18) : nontoxic tracer for rapid tumor detection. *J. Nucl. Med.*, 21:670-675, 1980.
 - 16) Glunde, K., Bhujwala, Z. M., Ronen, S. M. :Choline metabolism in malignant transformation. *Nat. Rev. Cancer*, 11:835-848, 2011.
 - 17) Podo, F. :Tumour phospholipid metabolism. *NMR Biomed.*, 12:413-439, 1999.
 - 18) Treglia, G., Giovannini, E., Di Franco, D., Calcagni, M. L., Rufini, V., Picchio, M., Giordano, A. :The role of positron emission tomography using carbon-11 and fluorine-18 choline in tumors other than prostate cancer: a systematic review. *Ann. Nucl. Med.*, 26:451-461, 2012.
 - 19) DeGrado, T. R., Baldwin, S. W., Wang, S., Orr, M. D., Liao, R. P., Friedman, H. S., Reiman, R., Price, D. T., Coleman, R. E. :Synthesis and evaluation of (18) F-labeled choline analogs as oncologic PET tracers. *J. Nucl. Med.*, 42:1805-1814, 2001.
 - 20) Moon, S. H., Hyun, S. H., Choi, J. Y. :Prognostic significance of volume-based PET parameters in cancer patients. *Korean J. Radiol.*, 14:1-12, 2013.
 - 21) Pak, K., Cheon, G. J., Nam, H. Y., Kim, S. J., Kang, K. W., Chung, J. K., Kim, E. E., Lee, D. S. :Prognostic value of metabolic tumor volume and total lesion glycolysis in head and neck cancer: a systematic review and meta-analysis. *J. Nucl. Med.*, 55:884-890, 2014.
 - 22) Kitagawa, Y., Sano, K., Nishizawa, S., Nakamura, M., Ogasawara, T., Sadato, N., Yonekura, Y. :FDG-PET for prediction of tumour aggressiveness and response to intra-arterial chemotherapy and radiotherapy in head and neck cancer. *Eur. J. Nucl. Med. Mol. Imaging*, 30:63-71, 2003.
 - 23) Kunkel, M., Forster, G. J., Reichert, T. E., Jeong, J. H., Benz, P., Bartenstein, P., Wagner, W., Whiteside, T. L. :Detection of recurrent oral squamous cell carcinoma by [18F] -2-fluorodeoxyglucose-positron emission tomography: implications for prognosis and patient management. *Cancer*, 98:2257-2265, 2003.
 - 24) Wong, R. J., Lin, D. T., Schoder, H., Patel, S. G., Gonen, M., Wolden, S., Pfister, D. G., Shah, J. P., Larson, S. M., Kraus, D. H. :Diagnostic and prognostic value of [(18) F] fluorodeoxyglucose positron emission tomography for recurrent head and neck squamous cell carcinoma. *J. Clin. Oncol.*, 20:4199-4208, 2002.
 - 25) Huyge, V., Garcia, C., Vanderstappen, A., Alexiou, J., Gil, T., Flamen, P. :Progressive osteoblastic bone metastases in breast cancer negative on FDG-PET. *Clin. Nucl. Med.*, 34:417-420, 2009.
 - 26) Nakai, T., Okuyama, C., Kubota, T., Yamada, K., Ushijima, Y., Taniike, K., Suzuki, T., Nishimura, T. :Pitfalls of FDG-PET for the diagnosis of osteoblastic bone metastases in patients with breast cancer. *Eur. J. Nucl. Med. Mol. Imaging*, 32:1253-1258, 2005.
 - 27) Kubota, K., Furumoto, S., Iwata, R., Fukuda, H., Kawamura, K., Ishiwata, K. :Comparison of 18F-fluoromethylcholine and 2-deoxy-D-glucose in the distribution of tumor and inflammation. *Ann. Nucl. Med.*, 20:527-533, 2006.
 - 28) Kubota, R., Yamada, S., Kubota, K., Ishiwata, K., Tamahashi, N., Ido, T. :Intratumoral distribution of fluorine-18-fluorodeoxyglucose in vivo: high accumulation in macrophages and granulation tissues studied by microautoradiography. *J. Nucl. Med.*, 33:1972-1980, 1992.
 - 29) Ishikuro, M., Sakamoto, K., Kayamori, K., Akashi, T., Kanda, H., Izumo, T., Yamaguchi, A. :Significance of the fibrous stroma in bone invasion by human gingival squamous cell carcinomas. *Bone*, 43:621-627, 2008.
 - 30) Kayamori, K., Sakamoto, K., Nakashima, T., Takayanagi, H., Morita, K., Omura, K., Nguyen, S. T., Miki, Y., Iimura, T., Himeno, A., Akashi, T.,

- Yamada-Okabe, H., Ogata, E., Yamaguchi, A. :Roles of interleukin-6 and parathyroid hormone-related peptide in osteoclast formation associated with oral cancers: significance of interleukin-6 synthesized by stromal cells in response to cancer cells. *Am. J. Pathol.*, 176:968-980, 2010.
- 31) Abe, K., Sasaki, M., Kuwabara, Y., Koga, H., Baba, S., Hayashi, K., Takahashi, N., Honda, H. :Comparison of 18FDG-PET with 99mTc-HMDP scintigraphy for the detection of bone metastases in patients with breast cancer. *Ann. Nucl. Med.*, 19:573-579, 2005.
- 32) Ghanem, N., Uhl, M., Brink, I., Schafer, O., Kelly, T., Moser, E., Langer, M. :Diagnostic value of MRI in comparison to scintigraphy, PET, MS-CT and PET/CT for the detection of metastases of bone. *Eur. J. Radiol.*, 55:41-55, 2005.
- 33) Slootweg, P. J., Muller, H. :Mandibular invasion by oral squamous cell carcinoma. *J. Craniomaxillofac. Surg.*, 17:69-74, 1989.
- 34) Totsuka, Y., Usui, Y., Tei, K., Kida, M., Mizukoshi, T., Notani, K., Fukuda, H. :Results of surgical treatment for squamous carcinoma of the lower alveolus: segmental vs. marginal resection. *Head Neck*, 13:114-120, 1991