Atherosclerosis 260 (2017) 87–93

Contents lists available at ScienceDirect

Atherosclerosis

journal homepage: www.elsevier.com/locate/atherosclerosis

Preoperative cervical carotid artery contrast-enhanced ultrasound findings are associated with development of microembolic signals on transcranial Doppler during carotid exposure in endarterectomy

Kohki Oikawa [a], Tadayoshi Kato [b], Kazumasa Oura [b], Shinsuke Narumi [b], Makoto Sasaki [c], Shunrou Fujiwara [a], Masakazu Kobayashi [a], Yoshiyasu Matsumoto [a], Jun-ichi Nomura [a], Kenji Yoshida [a], Yasuo Terayama [b], Kuniaki Ogasawara [a, *]

[a] Department of Neurosurgery, Iwate Medical University School of Medicine, Morioka, Japan
[b] Department of Neurology and Gerontology, Iwate Medical University School of Medicine, Morioka, Japan
[c] Division of Ultrahigh Field MRI, Institute for Biomedical Sciences, Iwate Medical University School of Medicine, Morioka, Japan

ARTICLE INFO

Article history:
Received 21 January 2017
Received in revised form
27 February 2017
Accepted 17 March 2017
Available online 19 March 2017

Keywords:
Carotid endarterectomy
Ultrasound
Contrast enhancement
Microembolic signals

ABSTRACT

Background and aims: Emboli from the surgical site during exposure of the carotid arteries cause new cerebral ischemic lesions or neurological deficits after carotid endarterectomy (CEA). The purpose of the present study was to determine whether preoperative contrast-enhanced ultrasound findings of the cervical carotid arteries are associated with the development of microembolic signals (MES) on transcranial Doppler, during exposure of the arteries in CEA, and to compare the predictive accuracy of contrast-enhanced ultrasound findings with that of gray-scale median (GSM).
Methods: Seventy patients with internal carotid artery stenosis (≥70%) underwent preoperative cervical carotid artery ultrasound and CEA under transcranial Doppler monitoring of MES in the ipsilateral middle cerebral artery. Maximally enhanced intensities on the intraplaque and lumen time-intensity curves, respectively, were obtained from contrast-enhanced ultrasonography data, and the ratio of the maximal intensity (EI_p) of the intraplaque curve to that (EI_l) of the lumen curve was calculated. The GSM value of the plaque was also measured.
Results: The area under the receiver operating characteristic curve to discriminate between the presence and absence of MES during exposure of the carotid arteries was significantly greater for EI_p/EI_l than for GSM ($p = 0.0108$). Multivariate statistical analysis demonstrated that only EI_p/EI_l was significantly associated with the development of MES during exposure of the carotid arteries ($p = 0.0002$).
Conclusions: Preoperative contrast-enhanced ultrasound findings of the cervical carotid arteries are associated with development of MES on transcranial Doppler during exposure of the arteries in CEA, and the predictive accuracy of contrast-enhanced ultrasound is greater than that of GSM.

1. Introduction

Carotid endarterectomy (CEA) can prevent stroke in appropriately selected patients [1–3], but >70% of intraoperative procedure-related strokes are caused by cerebral emboli from the surgical site [4]. Emboli from the surgical site can be detected as microembolic signals (MES) on intraoperative transcranial Doppler (TCD) monitoring of the middle cerebral artery (MCA) [4–8]. Detection of MES during exposure of the carotid arteries has been shown to be significantly correlated with new ischemic lesions or neurological deficits following CEA [5–8]. Solid masses, such as thrombi, can be present on the surface of internal carotid artery (ICA) plaque, and carotid artery manipulation to expose them during the CEA procedure may result in the masses being dislodged, causing cerebral ischemic lesions [9]. It has been reported that intraplaque hemorrhage is related to a histologically disrupted plaque surface, which suggests that, under such conditions, thrombi are exposed to blood flow in carotid artery stenosis [10]. Histological neovascularization predicts carotid plaque vulnerability [11–13], and neovessels are

* Corresponding author. Department of Neurosurgery, Iwate Medical University, 19-1 Uchimaru, Morioka 020-8505, Japan.
E-mail address: kuogasa@iwate-med.ac.jp (K. Ogasawara).

http://dx.doi.org/10.1016/j.atherosclerosis.2017.03.026

immature and fragile because local inflammatory damage and shear stress from the arterial lumen lead to collapse, causing intraplaque hemorrhage [12,14]. Thus, risk stratification for patients being considered for CEA can be improved by preoperative identification of plaque vulnerability based on the degree of neovascularization.

Cervical carotid artery ultrasound is widely used for bedside evaluation of the morphology of this artery, in particular, to characterize intraplaque components for determination of vulnerable plaques. A vulnerable plaque is generally seen as a hypoechoic plaque, but there is considerable overlap among components of plaque echogenicity, even with quantitative evaluation, such as with gray-scale median (GSM) [15,16]. Furthermore, plaque echogenicity does not always accurately predict the development of MES during CEA [8,17].

Contrast-enhanced ultrasound can generate real-time images of microbubbles as intravascular tracers that penetrate the plaque from the vessel lumen or adventitial side through neovessels [18–20]. In particular, second-generation contrast agents containing less soluble gases, such as Sonazoid (GE Healthcare, Oslo, Norway), are stable *in vivo* and provide stable contrast because they are highly compressible and facilitate detection of small and low-flow vessels, such as neovessels in carotid plaques [14,18]. Recent studies demonstrated that visual or quantitative evaluation of the contrast effect using contrast-enhanced ultrasound enabled the histopathological assessment of neovascularization of the carotid plaque, suggesting that the high contrast effect in plaque may reliably predict the presence of rich neovessels, plaque rupture, and intraplaque hemorrhage [12,14,18,21,22].

The purpose of the present study was to determine whether preoperative contrast-enhanced ultrasound findings of the cervical carotid arteries are associated with development of MES on TCD during exposure of the arteries in CEA and to compare the predictive accuracy of contrast-enhanced ultrasound findings with that of GSM.

2. Patients and methods

2.1. Study design

The present study was a prospective observational study. The study protocol conformed to the ethical guidelines of the 1975 Declaration of Helsinki. The institutional ethics committee reviewed and approved the protocol, and all patients or their next of kin provided their written, informed consent prior to the patients' participation.

2.2. Inclusion criteria of patients

Patients with ipsilateral ICA stenosis ≥70% determined according to the below-mentioned method with useful preoperative residual function (modified Rankin scale score, 0–2) and who underwent CEA of the carotid bifurcation in our institution were included. Patients with previous allergic reactions to Sonazoid or eggs [14], those who did not undergo preoperative contrast-enhanced ultrasound, and those without reliable TCD monitoring throughout the entire operation because of failure to obtain an adequate bone window were excluded.

2.3. Angiography and measurement of the degree of ICA stenosis

All patients underwent angiography with arterial catheterization, and the degree of ICA stenosis was determined using the North American Symptomatic Carotid Endarterectomy Trial (NASCET) criteria [3] and based on the comment of Fox et al. [23], as follows [24]. The distal ICA was measured beyond the bulb, where the walls are parallel and no longer tapering. To prevent underestimation of percentage stenosis for the distal ICA with reduced axial diameter due to near occlusion, if the diameter of the coaxial section of the distal ICA was at least 80% smaller than the diameter on the contralateral side, the diameter of the contralateral distal ICA was substituted for calculating the degree of stenosis of the affected ICA. If the contralateral ICA was occluded or stenotic (>70%) and the diameter of the distal ICA on the affected side was less than the diameter of the distal external carotid artery, the diameter of the distal external carotid artery was substituted for calculating the degree of stenosis of the affected ICA. The required diameter of each artery was measured on the workstation.

2.4. Pre-, intra- and postoperative management

Antiplatelet therapy was given to all patients until the morning of the day of CEA. The procedure was performed under general anesthesia with an operative microscope through a skin incision by only one senior neurosurgeon blinded to preoperative ultrasound findings, as well as intraoperative TCD findings. The neurosurgeon continued the procedure regardless of the intraoperative TCD findings. During anesthesia, standard electrocardiography, direct arterial blood pressure measurements through an intra-arterial catheter, pulse oximetry, and capnography were routinely monitored. During carotid artery exposure, the increase in systolic blood pressure was in principle maintained at least 10% above the preoperative value [23]. A vasodilator (nicardipine or nitroglycerin) or a vasoconstrictor (theoadrenalin) was administered intravenously as needed. Intraluminal shunts or patch grafts were used in none of these procedures. Heparin (5000 IU) was given as a bolus before ICA clamping.

2.5. Cervical carotid artery ultrasound and data processing

Cervical carotid artery ultrasound was performed on the affected side using an ultrasound scanner (VOLSON E8 EXPERT, GE Healthcare, Milwaukee, WI) with a 9L probe (3.1–7.9 MHz) by one investigator, three days before surgery, and all images were stored on the hard disk drive of the scanner. First, a carotid plaque was identified on B-, color Doppler-, and pulse Doppler-mode images. Next, contrast-enhanced ultrasonography was performed using a coded phase inversion mode (frame rate, 30 frames/s; image depth, 4–5 cm; transit focus, 3–4 cm) with a low mechanical index (0.1–0.2). Data were continuously recorded from 10 s before an intravenous bolus injection (0.01 ml/kg body weight) of a contrast agent (Sonazoid, Daiichi-Sankyo/GE, Tokyo, Japan) over 70 s (Fig. 1A). A low mechanical index was used for the minimal destruction of the microbubbles produced by the contrast agent.

Raw data of contrast-enhanced ultrasonography were transferred to the workstation. One investigator, who was blinded to patient information, manually placed multiple circular regions of interest (ROIs) within the carotid plaque on the sagittal section of a coded phase inversion image so that ROIs extended all over the plaque and were located near the lumen of the carotid artery (Fig. 1B). Regions with acoustic shadows due to calcification were excluded from the ROIs. The same investigator also manually placed a circular ROI at each of the proximal and distal portions within the lumen of the carotid artery on the same image (Fig. 1B). Time-intensity curves of the intraplaque and lumen ROIs were generated from the raw data using echo analyzing software (VolMap445 ver.1.1.2a2, YD, Ikoma, Nara, Japan). Each original time-intensity curve was output as a csv file by the software. Using Microsoft Excel 2016 (Microsoft Corporation, Redmond, WA), time-intensity curves were averaged with respect to intraplaque ROIs

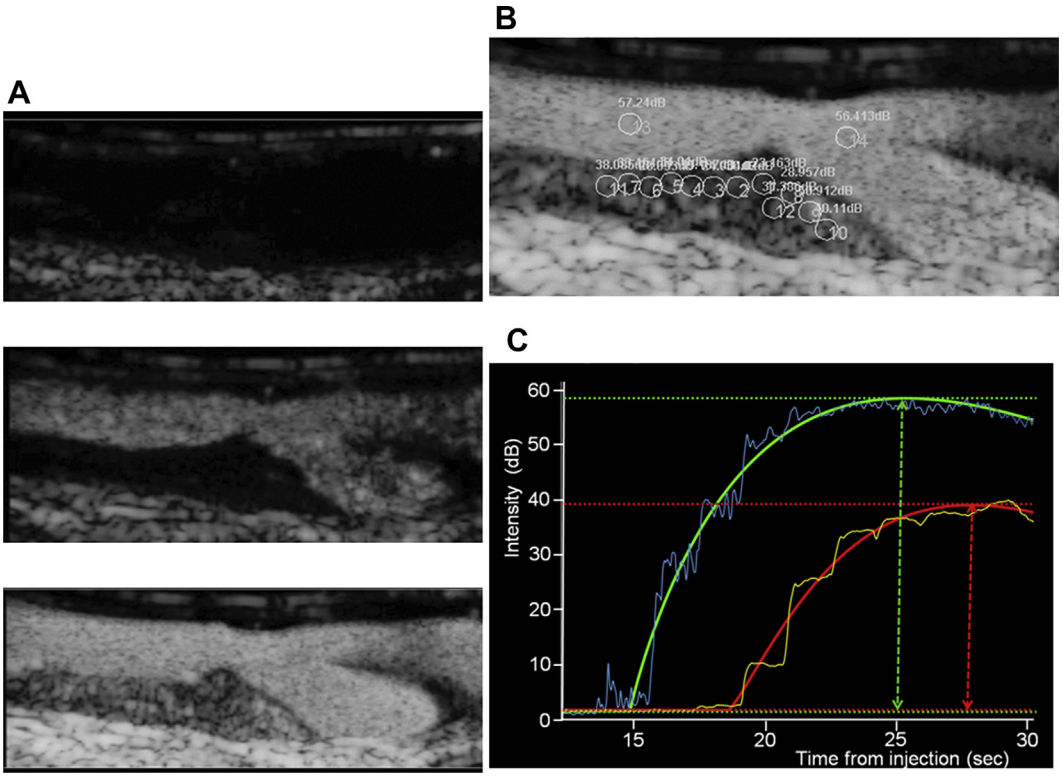

Fig. 1. 73-year-old man with symptomatic right internal carotid artery stenosis (90%) showing microembolic signals (MES) during exposure of the carotid arteries in endarterectomy.
(A) Sequence of coded phase inversion images obtained before and after the intravenous injection of ultrasound contrast. When compared with an image before the injection (upper panel), only the lumen of the carotid artery is enhanced 18 s after the injection (middle panel). Nine seconds later (27 s after the injection), the carotid plaque is entirely enhanced (lower panel). (B) Multiple circular regions of interest (ROIs) are set within the carotid plaque and near the lumen of the carotid artery, and two ROIs are set at the proximal and distal portions, respectively, within the lumen of the carotid artery. (C) Time-intensity curves of the intraplaque and lumen ROIs. Blue and yellow lines indicate averaged and smoothed time-intensity curves of the intraplaque and lumen ROIs, respectively. Green and red curves indicate fitted time-intensity curves of the intraplaque and lumen ROIs, respectively. The length of a bidirectional arrow indicates intensity enhanced maximally by ultrasound contrast.

and lumen ROIs in each patient, and each averaged time-intensity curve was smoothed by averaging intensities of the 20 time points neighboring each time point. Next, a curve-fitting technique was applied for the smoothed time-intensity curves of intraplaque ROIs and of lumen ROIs. The gamma variate curve was used for the fitting because of the bolus injection of the contrast media [25]. All fitting analyses were performed on MATLAB R2015b (MathWorks, Natick, MA). A baseline intensity (dB) before injection of contrast agent and a maximal intensity (dB) after the injection were obtained on the intraplaque and lumen curves after the fitting in each patient (Fig. 1C). The enhanced intensity (EI) was calculated by subtracting the baseline intensity from the maximal intensity on the intraplaque (EI_p) and lumen (EI_l) curves (Fig. 1C). The ratio of the EI_p to EI_l was then finally calculated for each patient.

Next, a B-mode sagittal image of each patient was exported in JPEG format. On this JPEG image, the same investigator who analyzed data of contrast-enhanced ultrasonography visually and manually set multiple irregular ROIs within the carotid plaque so that ROIs extended all over the plaque and were located near the lumen of the carotid artery (Fig. 2). Regions with acoustic shadows due to calcification were excluded from the ROIs. The GSM value of each ROI was then measured after normalization of the gray-scale (0 for the arterial lumen and 195 for the arterial adventitia) using a graphic software package (Photoshop CS4, Adobe Systems, San Jose, CA), as reported previously [16]. GSM values in intraplaque ROIs were then finally averaged in each patient.

2.6. TCD monitoring

TCD was performed using a PIONEER TC2020 system (EME, Uberlingen, Germany; software version 2.50, 2-MHz probe; diameter, 1.5 cm; insonation depth, 40–66 mm; scale, −100 and + 150 cm/s; sample volume, 2 mm; 64-point fast Fourier transform; fast Fourier transform length, 2 mm, fast Fourier transform overlap, 60%; high-pass filter, 100 Hz; detection threshold, 9 dB; minimum increase time, 10 ms) for insonation of the MCA ipsilateral to the carotid artery undergoing CEA [23]. TCD data were stored on a hard disk using a coding system and later analyzed manually by a clinical neurophysiologist blinded to patient information [23]. MES were identified during exposure of the carotid arteries (from skin incision to ICA clamping) according to the recommended guidelines [26].

2.7. Statistical analysis

Data are expressed as means ± standard deviation (SD). Relationships between EI_p/EI_l or averaged GSM and the development of MES during exposure of the carotid arteries were evaluated using the Mann-Whitney *U* test. The accuracy of the EI_p/EI_l or averaged GSM to predict the development of MES during exposure of the carotid arteries was determined using a receiver operating characteristic (ROC) curve, and the ability to discriminate between the presence and absence of MES during exposure of the carotid arteries was estimated using the area under the ROC curve (AUC).

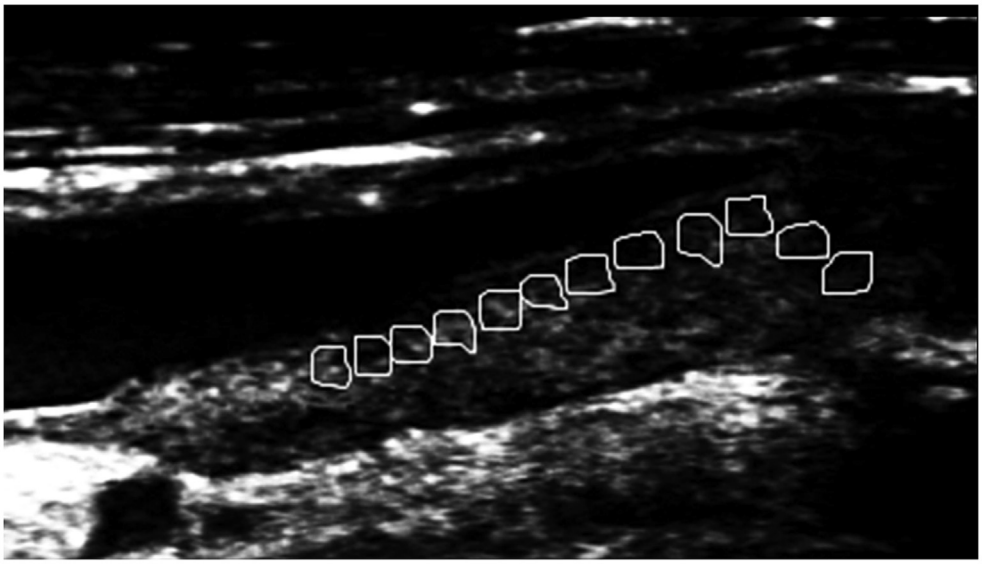

Fig. 2. B-mode image of the patient identical to Fig. 1.
Multiple irregular ROIs are set within the carotid plaque and near the lumen of the carotid artery.

Pairwise comparison of the AUCs was performed for the EI_p/EI_l and averaged GSM using the method proposed by Pepe and Longton [27]. The relationships between the development of MES during exposure of the carotid arteries and each variable except EI_p/EI_l and averaged GSM were also evaluated by univariate analysis using the Mann-Whitney *U* test or the χ^2 test. Multivariate statistical analysis of factors related to the development of MES during exposure of the carotid arteries was performed using logistic regression modeling. EI_p/EI_l, averaged GSM, and variables showing values of $p < 0.2$ on univariate analyses were entered into the final model. For all statistical analyses, significance was set at the $p < 0.05$ level.

3. Results

During the 15-month period of the study, a total of 86 patients satisfied the inclusion criteria. Of these, one patient who underwent urgent CEA due to crescendo transient ischemic attacks did not undergo cervical carotid artery contrast-enhanced ultrasound. The remaining 85 patients did not have a previous allergic reaction to Sonazoid or eggs and underwent cervical carotid artery contrast-enhanced ultrasound followed by CEA, but in three patients, no ROIs could be placed within the carotid plaque because of an acoustic shadow due to heavy calcification in the whole plaque. These three patients were excluded from the analysis. For the remaining 82 patients, TCD was attempted, but 12 patients did not have reliable TCD monitoring throughout the entire operation because of failure to obtain an adequate bone window. These patients were excluded from analysis. Therefore, a total of 70 patients were enrolled into the present study.

The mean age of the 70 patients (66 men, 4 women) was 70 ± 8 years (range, 41–86 years). Sixty-two, 23, and 54 patients had hypertension, diabetes mellitus, and dyslipidemia, respectively. Fifty-five patients reported ipsilateral carotid territory symptoms within 6 months before surgery. Fifteen patients had asymptomatic ICA stenosis. The overall average degree of ICA stenosis was 86.3% ± 9.6% (range, 70–99%), with 8 patients showing >70% stenosis or occlusion in the contralateral ICA. Thirty-seven patients underwent left-sided CEA. The mean duration of ICA clamping was 36 min (range, 25–56 min).

None of the patients studied showed abnormal changes on intraoperative electrocardiography suggestive of acute cardiac events associated with maintaining the increase in systolic blood pressure. MES were detected in 19 of 70 patients (27%) when the ICA was manipulated to allow exposure from the carotid sheath.

None of the patients developed adverse effects of intravenous administration of the contrast agent. The numbers of ROIs placed within the plaque in each patient ranged from 2 to 16 (5 ± 3).

Fig. 3 shows the relationship between EI_p/EI_l or averaged GSM and development of MES during exposure of the carotid arteries. While EI_p/EI_l was significantly greater in patients with MES (0.666 ± 0.209) than in those without MES (0.324 ± 0.254) ($p < 0.0001$), averaged GSM did not differ between patients with (9.639 ± 6.301) and without MES (13.034 ± 8.021) ($p = 0.1537$).

Fig. 4 shows ROC curves for EI_p/EI_l and averaged GSM in predicting development of MES during exposure of the carotid arteries. AUCs for EI_p/EI_l and averaged GSM were 0.843 and 0.611, respectively. The AUC was significantly greater for EI_p/EI_l than for averaged GSM (difference between AUCs, 0.232; $p = 0.0108$). Sensitivity, specificity, and positive- and negative-predictive values for EI_p/EI_l at the cut-off point lying closest to the left upper corner of the ROC curve in predicting development of MES during exposure of the carotid arteries were 90%, 76%, 58%, and 95% (cut-off point = 0.441), respectively (Fig. 3).

Results of univariate analysis of factors related to the development of MES during exposure of the carotid arteries (except EI_p/EI_l and averaged GSM) are summarized in Table 1. None of the variables showed significant associations with the development of MES during exposure of the carotid arteries. For multivariate statistical analysis of factors related to the development of MES during exposure of the carotid arteries, male sex, EI_p/EI_l, and averaged GSM were adopted as confounders in the logistic regression model. The analysis revealed that only EI_p/EI_l was significantly associated with the development of MES during exposure of the carotid arteries (95% confidence intervals: 12.0–320.8; $p = 0.0002$).

4. Discussion

The present study demonstrated that preoperative contrast-enhanced ultrasound findings of the cervical carotid arteries are associated with development of MES on TCD during exposure of the

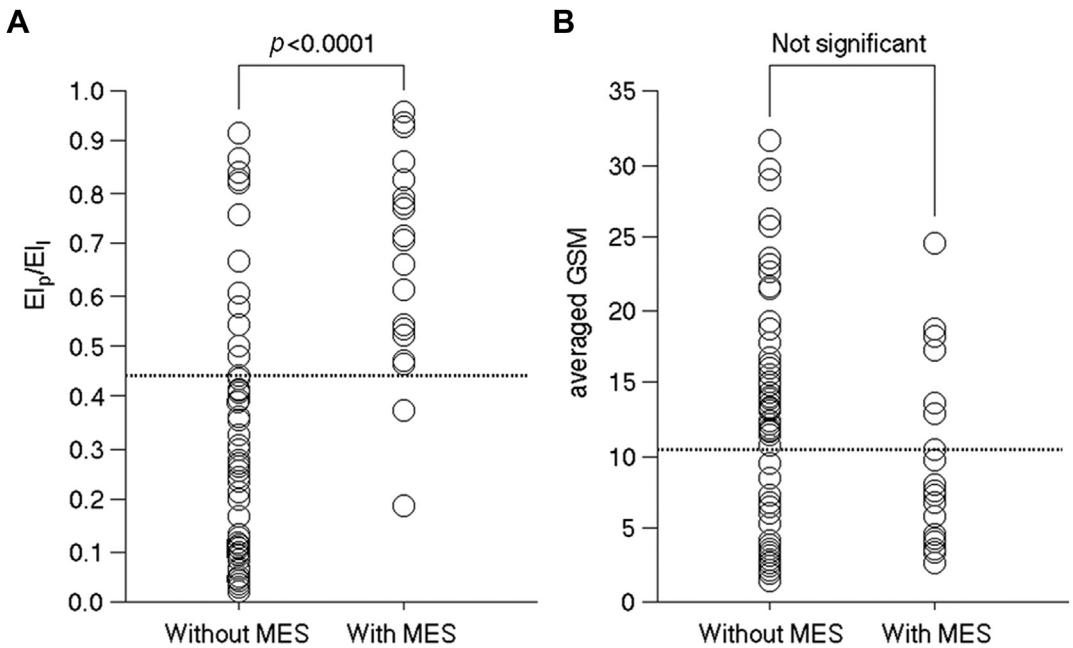

Fig. 3. Relationship between maximally enhanced intensity in the carotid plaque (EI_p)/maximally enhanced intensity in the carotid lumen (EI_l) (A) or averaged gray-scale median (GSM) (B) and development of MES during exposure of the carotid arteries.
Dashed horizontal lines denote the cutoff points lying closest to the left upper corners of the receiver operating characteristic (ROC) curves in predicting the development of MES during exposure of the carotid arteries.

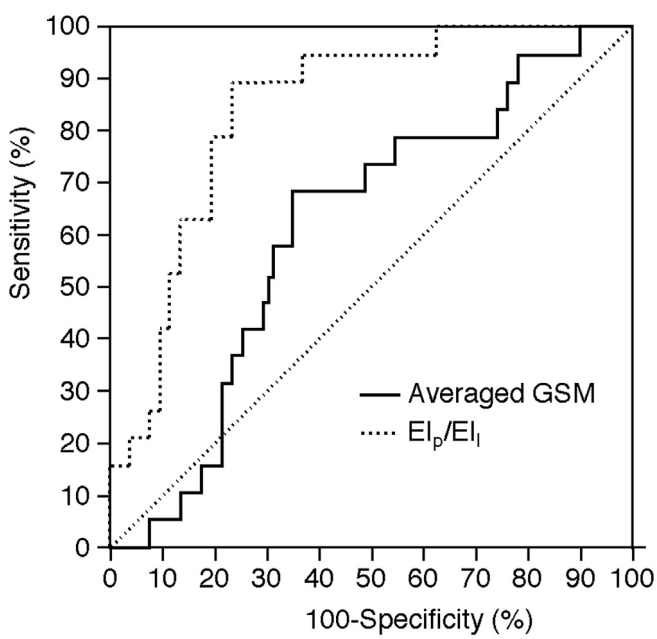

Fig. 4. ROC curves used to compare accuracy between EI_p/EI_l and averaged GSM for predicting the development of MES during exposure of the carotid arteries.
Pairwise comparison analysis shows a significantly greater area under the ROC curve for EI_p/EI_l (solid line) than that for averaged GSM (dotted line).

carotid arteries in CEA, and the predictive accuracy of contrast-enhanced ultrasound is greater than that of GSM.

In the present study, the degree of enhancement of the carotid plaque on preoperative contrast-enhanced ultrasound was significantly greater in patients with MES during exposure of the carotid arteries than in those without MES, and greater enhancement was an independent predictor of the development of MES. These data supported previous findings that neovascularization is associated with plaque vulnerability [11,13] and a plaque with rich neovessels is fragile [14]. Based on the present data, the degree of enhancement showed 90% sensitivity and a 95% negative-predictive value for predicting the development of MES. Thus, preoperative contrast-enhanced ultrasound for the cervical carotid arteries could identify patients at risk for development of artery-to-artery embolism during exposure of the carotid arteries in CEA as a clinical screening test. In contrast, its specificity and positive predictive value were relatively low. Pseudo-enhancement artifact interferes with the assessment of the microvasculature in the far wall of the carotid artery by contrast-enhanced ultrasound [28,29]. When ultrasound propagates through a medium containing contrast agent microbubbles, such as the carotid lumen, distortion of the transmitted waveforms can occur [30]. This can cause variable distortions of the waveforms in a pulse sequence, with a resultant echo signal from tissue behind the contrast pool (e.g. adventitia) that is similar to the response of contrast agent microbubbles [30]. Thus, it is possible to misclassify the tissue behind the contrast pool as microbubbles [31]. Therefore, overestimation of the contrast-enhanced intensity of plaque in the far wall of the carotid artery can occur due to inclusion of this artifact in the measurements. This may be a reason for the relatively low specificity and positive predictive value of the contrast-enhanced ultrasound findings in the present study.

In the present study, the predictive accuracy of GSM for the development of MES was significantly lower than that of contrast-enhanced ultrasound. Further, preoperative GSM did not differ between patients with and without MES during exposure of the arteries, and it was not an independent predictor of the development of MES. These results corresponded with previous findings [8,17] and might be caused by the plaque echogenicity showing substantial overlap among different intraplaque components [15,16].

The present findings can be applied to clamping the common and external carotid arteries before manipulation of the carotid bulb and the ICA during carotid artery exposure in CEA [32]. This

Table 1
Univariate analysis of factors related to the development of MES during exposure of the carotid arteries.

Variables	Development of MES		*p* value
	Yes (n = 19)	No (n = 51)	
Age (years, mean ± SD)	69.7 ± 9.1	70.4 ± 7.1	0.7961
Male sex	16 (84%)	50 (98%)	0.0581
Hypertension	17 (89%)	45 (88%)	>0.9999
Diabetes mellitus	5 (26%)	18 (35%)	0.5745
Dyslipidemia	13 (68%)	41 (80%)	0.3425
Symptomatic lesion	16 (84%)	39 (76%)	0.7441
Degree of ICA stenosis (%, mean ± SD)	87.4 ± 8.7	85.9 ± 10.0	0.6698
Bilateral lesions	2 (11%)	6 (12%)	>0.9999
Left-sided CEA	11 (58%)	26 (51%)	0.7884
Duration of ICA clamping (min, mean ± SD)	37.5 ± 5.9	36.7 ± 7.0	0.4159

MES, microembolic signals; SD, standard deviation; ICA, internal carotid artery; CEA, carotid endarterectomy.

early clamping of the carotid arteries results in reversal of blood flow in the ipsilateral ICA and prevention of cerebral embolism from the surgical site [32]. However, this procedure causes a longer duration of cerebral ischemia [32]. Therefore, given these findings and the present data, a practical clinical algorithm to prevent the development of MES in CEA can be proposed: patients undergo preoperative cervical carotid artery contrast-enhanced ultrasound; when the EI_p/EI_l is high (≥0.441), early clamping of the carotid arteries is performed during carotid artery exposure; and when the value is low (<0.441), this procedure is unnecessary.

A recent study has demonstrated that the incidence of the development of MES was higher while deploying distal filter protection in carotid artery stenting than during carotid artery exposure in CEA, and that carotid artery stenting with blood flow reversal using early balloon occlusion of the common and external carotid arteries significantly reduced the incidence of MES when compared to carotid artery stenting using only distal filter protection [33]. The present findings might also suggest that patients with a greater degree of enhancement of the carotid plaque on preoperative contrast-enhanced ultrasound should undergo carotid artery stenting with blood flow reversal rather than that using only distal filter protection, although the present study did not include any patients undergoing carotid artery stenting.

Besides a pseudo-enhancement artifact in the far wall on contrast-enhanced ultrasound as described above, the present study possesses several limitations that require discussion. First, processing the raw data of contrast-enhanced ultrasonography to fitted time-intensity curves is very complex, and thus, the present method is not easily applicable in clinical practice. Second, patients with previous allergic reaction to eggs could not receive Sonazoid as an intravascular tracer in the present study because the lipid-stabilized suspension of Sonazoid contains egg yolk [14,18]. Third, for carotid plaque with heavy calcification, ROIs cannot be placed within the carotid plaque on ultrasound images because of acoustic shadows [18]. Lastly, to measure a contrast-enhanced effect and GSM, ROIs within the carotid plaque were set on a coded phase inversion image and on a B-mode image, respectively. These ROIs were not identical between the two images, because ROI setting was visually and manually performed due to a lack of software for automatic ROI setting.

In conclusion, the present study demonstrated that preoperative contrast-enhanced ultrasound findings of the cervical carotid arteries are associated with the development of MES on TCD during carotid artery exposure in CEA, and the predictive accuracy of contrast-enhanced ultrasound is greater than that of GSM.

Author contributions

Kohki Oikawa, Makoto Sasaki and Kuniaki Ogasawara conceived and designed the study; Kohki Oikawa, Tadayoshi Kato, Kazumasa Oura and Shinsuke Narumi performed measurements and analyses of cervical carotid artery contrast-enhanced ultrasound; Masakazu Kobayashi, Yoshiyasu Matsumoto and Jun-ichi Nomura performed measurements and analyses of MES on TCD; Shunrou Fujiwara and Kenji Yoshida analyzed the data; Yasuo Terayama critically revised the manuscript and helped with interpretation of the results; and Kohki Oikawa and Kuniaki Ogasawara wrote the paper.

Conflict of interest

Kuniaki Ogasawara declared the following potential conflicts of interest with respect to the research, authorship, and/or publication of this article: consigned research funds from Nihon Medi-Physics Co., Ltd. (3,000,000 yen) and Bristol-Myers Squibb (5,000,000 yen).

Financial support

This work was partly supported by a Grant-in-Aid for Strategic Medical Science Research from the Ministry of Education, Culture, Sports, Science and Technology of Japan (S1491001); and Scientific Research from Japan Society for the Promotion of Science (JP15K10313).

References

[1] P.M. Rothwell, M. Eliasziw, S.A. Gutnikov, A.J. Fox, D.W. Taylor, et al., Analysis of pooled data from the randomised controlled trials of endarterectomy for symptomatic carotid stenosis, Lancet 361 (2003) 107–116.
[2] Executive Committee for the Asymptomatic Carotid Atherosclerosis Study, Endarterectomy for asymptomatic carotid artery stenosis, J. A. M. A 273 (1995) 1421–1428.
[3] North American Symptomatic Carotid Endarterectomy Trial Collaborators, Beneficial effect of carotid endarterectomy in symptomatic patients with high-grade carotid stenosis, N. Engl. J. Med. 325 (1991) 445–453.
[4] M.P. Spencer, Transcranial Doppler monitoring and causes of stroke from carotid endarterectomy, Stroke 28 (1997) 685–691.
[5] R.G. Ackerstaff, K.G. Moons, C.J. van de Vlasakker, F.L. Moll, F.E. Vermeulen, et al., Association of intraoperative transcranial Doppler monitoring variables with stroke from carotid endarterectomy, Stroke 31 (2000) 1817–1823.
[6] O. Wolf, P. Heider, M. Heinz, H. Poppert, D. Sander, et al., Microembolic signals detected by transcranial Doppler sonography during carotid endarterectomy and correlation with serial diffusion-weighted imaging, Stroke 35 (2004) e373–e375.
[7] B.A. Verhoeven, J.P. de Vries, G. Pasterkamp, R.G. Ackerstaff, A.H. Schoneveld, et al., Carotid atherosclerotic plaque characteristics are associated with microembolization during carotid endarterectomy and procedural outcome, Stroke 36 (2005) 1735–1740.
[8] M.E. Gaunt, P.J. Martin, J.L. Smith, T. Rimmer, G. Cherryman, et al., Clinical relevance of intraoperative embolization detected by transcranial Doppler ultrasonography during carotid endarterectomy: a prospective study of 100 patients, Br. J. Surg. 81 (1994) 1435–1439.
[9] J.A. Rosario, V.C. Hachinski, D.H. Lee, A.J. Fox, Adverse reactions to duplex scanning, Lancet 330 (1987) 1023.
[10] A.C. Van Dijk, M.T. Truijman, B. Hussain, T. Zadi, G. Saiedie, et al., Intraplaque

hemorrhage and the plaque surface in carotid atherosclerosis: the plaque at risk study (PARISK), A.J.N.R. Am. J. Neuroradiol. 36 (2015) 2127–2133.
[11] S. Jander, M. Sitzer, R. Schumann, M. Schroeter, M. Siebler, et al., Inflammation in high-grade carotid stenosis: a possible role for macrophages and T cells in plaque destabilization, Stroke 29 (1998) 1625–1630.
[12] D. Staub, S. Partovi, A.F.L. Schinkel, B. Coll, H. Uthoff, et al., Correlation of carotid artery atherosclerotic lesion echogenicity and severity at standard US with intraplaque neovascularization detected at contrast enhanced US, Radiology 258 (2011) 618–626.
[13] M.J. McCarthy, I.M. Loftus, M.M. Thompson, L. Jones, N.J. London, et al., Angiogenesis and the atherosclerotic carotid plaque: an association between symptomatology and plaque morphology, J. Vasc. Surg. 30 (1999) 261–268.
[14] K. Saito, K. Nagatsuka, H. Ishibashi-Ueda, A. Watanabe, H. Kannki, et al., Contrast-enhanced ultrasound for the evaluation of neovascularization in atherosclerotic carotid artery plaques, Stroke 45 (2014) 3073–3075.
[15] M.M. Sabetai, T.J. Tegos, A.N. Nicolaides, S. Dhanjil, G.J. Pare, et al., Reproducibility of computer-quantified carotid plaque echogenicity: can we overcome the subjectivity? Stroke 31 (2000) 2189–2196.
[16] R. Sztajzel, S. Momjian, I. Momjian-Mayor, N. Murith, K. Djebaili, et al., Stratified gray-scale median analysis and color mapping of the carotid plaque: correlation with endarterectomy specimen histology of 28 patients, Stroke 36 (2005) 741–745.
[17] M.E. Gaunt, L. Brown, T. Hartshorne, P.R. Bell, A.R. Naylor, Unstable carotid plaques: preoperative identification and association with intraoperative embolisation detected by transcranial Doppler, Eur. J. Vasc. Endovasc. Surg. 11 (1996) 78–82.
[18] G. Varetto, L. Gibello, C. Castagno, S. Quaglino, M. Ripepi, et al., Use of contrast-enhanced ultrasound in carotid atherosclerotic disease: limits and perspectives, Biomed. Res. Int. 2015 (2015) 93163.
[19] D. Staub, S. Partovi, S. Imfeld, H. Uthoff, T. Baldi, et al., Novel applications of contrast-enhanced ultrasound imaging in vascular medicine, Vasa 42 (2013) 17–31.
[20] G.L. Ten Kate, S.C. van den Oord, E.J. Sijbrands, A. van der Lugt, N. de Jong, et al., Current status and future developments of contrast-enhanced ultrasound of carotid atherosclerosis, J. Vasc. Surg. 57 (2013) 539–546.
[21] Q. Zhang, C. Li, H. Han, W. Dai, J. Shi, et al., Spatio-temporal quantification of carotid plaque neovascularization oncontrast enhanced ultrasound: correlation with visual grading and histopathology, Eur. J. Vasc. Endovasc. Surg. 50 (2015) 289–296.
[22] L. Xiong, Y.B. Deng, Y. Zhu, Y.N. Liu, X.J. Bi, Correlation of carotid plaque neovascularization detected by using contrast enhanced US with clinical symptoms, Radiology 251 (2009) 583–589.
[23] A.J. Fox, S.P. Symons, R.I. Aviv, P. Howard, R. Yeung, E.S. Bartlett, Falsely claiming use of NASCET percentage stenosis method, Radiology 253 (2009) 574–575.
[24] Y. Sato, K. Ogasawara, S. Narumi, M. Sasaki, A. Saito, E. Tsushima, et al., Optimal magnetic resonance plaque imaging for cervical carotid artery stenosis in predicting development of microembolic signals during exposure of carotid arteries in endarterectomy: comparison of four T1-weighted imaging techniques, AJNR Am. J. Neuroradiol. 37 (2016) 1146–1154.
[25] M.J. Blomley, P. Dawson, Bolus dynamics: theoretical and experimental aspects, Br. J. Radiol. 70 (1997) 351–359.
[26] Consensus Committee of the Ninth International Cerebral Hemodynamic Symposium, Basic identification criteria of Doppler microembolic signals, Stroke 26 (1995) 1123.
[27] M.S. Pepe, G. Longton, Standardizing diagnostic markers to evaluate and compare their performance, Epidemiology 16 (2005) 598–603.
[28] G.L. ten Kate, G.G. Renaud, Z. Akkus, S.C. van den Oord, F.J. ten Cate, et al., Far-wall pseudoenhancement during contrast-enhanced ultrasound of the carotid arteries: clinical description and in vitro reproduction, Ultrasound Med. Biol. 38 (2012) 593–600.
[29] A. Thapar, J. Shalhoub, M. Averkiou, C. Mannaris, A.H. Davies, et al., Dose-dependent artefact in the far wall of the carotid artery at dynamic contrast-enhanced US, Radiology 262 (2012) 672–679.
[30] S.C.H. van den Oord, G. Renaud, J.G. Bosch, N. de Jong, A.F.W. van der Steen, et al., Far wall pseudo-enhancement: a neglected artifact in carotid contrast-enhanced ultrasound? Atherosclerosis 229 (2013) 451–452.
[31] M.X. Tang, N. Kamiyama, R.J. Eckersley, Effects of nonlinear propagation in ultrasound contrast agent imaging, Ultrasound Med. Biol. 36 (2010) 459–466.
[32] M. Kobayashi, K. Ogasawara, T. Inoue, H. Saito, N. Komoribayashi, Y. Suga, et al., Urgent endarterectomy using pretreatment with free radical scavenger, edaravone, and early clamping of the parent arteries for cervical carotid artery stenosis with crescendo transient ischemic attacks caused by mobile thrombus and hemodynamic cerebral ischemia, Neurol. Med. Chir. (Tokyo) 47 (2007) 121–125.
[33] M. Plessers, I. Van Herzeele, D. Hemelsoet, N. Patel, E.M. Chung, G. Vingerhoets, et al., Transcervical carotid stenting with dynamic flow reversal demonstrates embolization rates comparable to carotid endarterectomy, J. Endovasc. Ther. 23 (2016) 249–254.